Method for Ejecting Cestodes: Duodenal Tube Injection of Gastrografin

Hiromichi Oi[1]
Hironobu Nakamura[1]
Toshio Nakabayashi[2]
Koji Waki[3]

Most of the conventional anthelmintics for cestodiasis are known to destroy the worm body. The risk of cysticercosis and recurrence of cestodiasis will be avoided only if tapeworms are ejected with intact bodies and scoleces. Two cases with *Diphyllobothrium latum* and two with *Taenia saginata* were treated by administration of 200–300 ml of Gastrografin through a duodenal tube. The worm bodies were confirmed by fluoroscopy, and the expelled worms were alive and had intact scoleces. No adverse effects were noted in the patients during or after the treatment.

Recently in Japan, parasitic infections such as ascariasis, ancylostomiasis, and trichuriasis caused by eating fresh vegetables or drinking polluted water have substantially decreased because of the mechanization of agriculture, the use of chemical fertilizers, and the improvement of environmental sanitation. On the other hand, taeniasis caused by eating raw beef and fish has shown a tendency to increase again after a decrease for some decades.

To treat taeniasis, many kinds of antiparasitics are administered orally and most of them produce antiparasitic effect by destroying the worm bodies. However, it is important to eject cestodes with intact scoleces and without destroying the worm body. The residual intact scolex in a patient's intestine causes recurrence of cestodiasis, and with *Taenia solium*, the broken proglottids release ova, which may cause dangerous cysticercosis.

We succeeded in treating two cases with *Diphyllobothrium latum* and two with *Taenia saginata* without destroying the worm bodies, by the administration of Gastrografin through a duodenal tube. Although the number of treated cases is still few, we believe that this method is a new and effective therapy for cestodiasis.

Subjects and Methods

The four patients, three men and one woman, aged 29–54 years, were diagnosed as having cestodiasis by detection of proglottids in stool samples. Each patient was given a dose of 1 g of magnesium oxide twice on the day before treatment: in the evening and before sleeping. On the day of treatment, the patient fasted in the morning. Under fluoroscopic guidance, a duodenal tube was inserted and the tip was advanced into the transverse part of the duodenum. Gastrografin (100 ml) was injected through the tube, and the worm body was confirmed fluoroscopically (fig. 1A). After administration of an additional 100–200 ml of Gastrografin, the worm body was propelled distad by peristalsis of the small intestine (figs. 1B and 1C). When the complete worm body was observed to have reached the rectum (fig. 1D), the patient was asked to defecate. Subsequently, the expelled worm body was examined to confirm that the scolex was intact.

Results

Two men (aged 29 and 39 years) had *Diphyllobothrium latum*, and one man (age 51) and the woman (age 54) had *Taenia saginata*. Each patient had one tapeworm

Received December 14, 1983; accepted after revision March 5, 1984.

Presented at the Asian Oceanian Congress of Radiology, Bangkok, November 1983.

[1] Department of Radiology, Research Institute for Microbial Diseases, Osaka University, 3-1 Yamadaoka, Suita, Osaka 565, Japan. Address reprint requests to H. Oi.

[2] Department of Parasitology, Research Institute for Microbial Diseases, Osaka University, Osaka 565, Japan.

[3] Department of Internal Medicine, Research Institute for Microbial Diseases, Osaka University, Osaka 565, Japan.

AJR 143:111–113, July 1984
0361–803X/84/1431–0111 $2.00

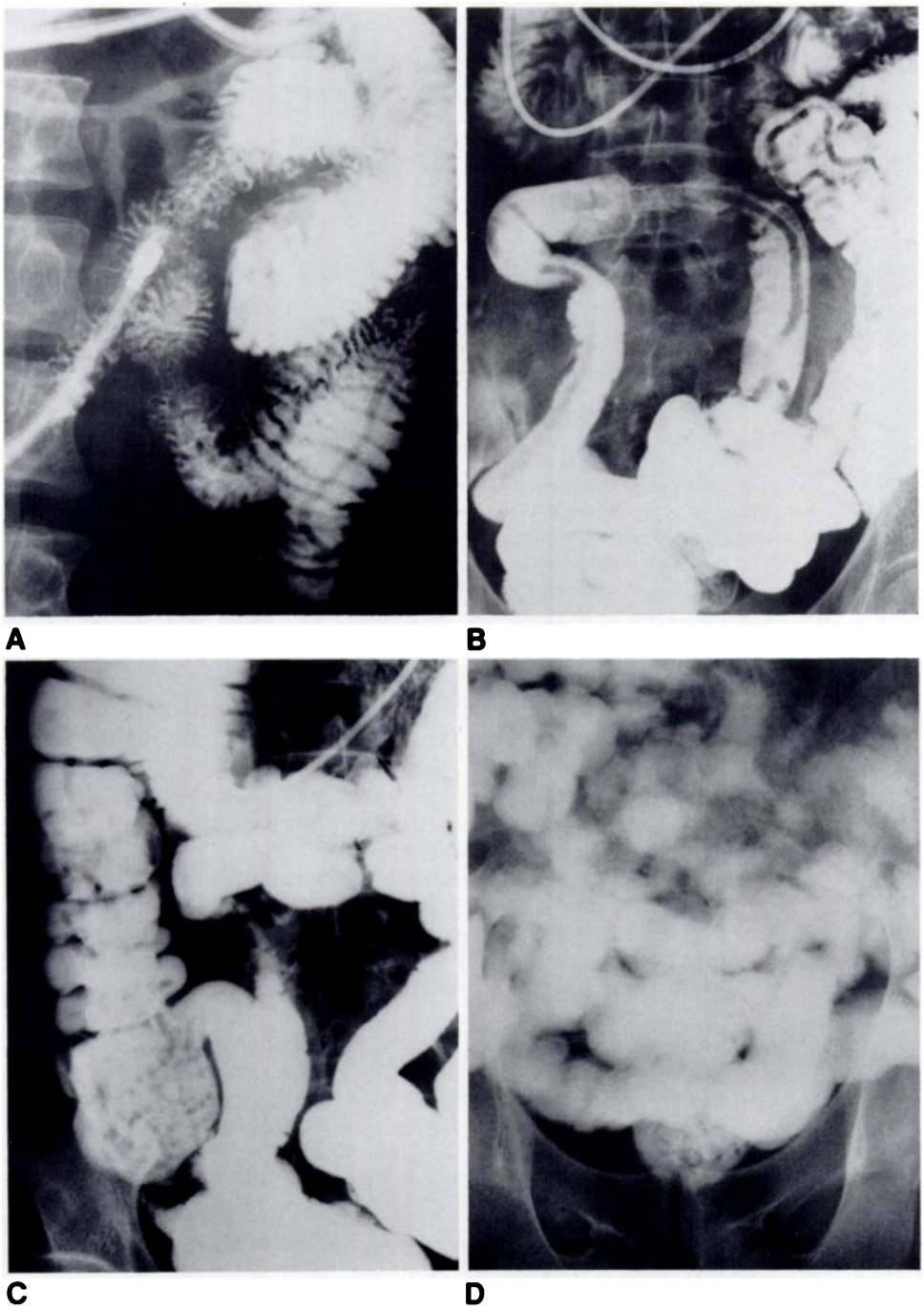

Fig. 1.—Three different patients. **A**, *Taenia saginata* is seen as filling defect in jejunum. **B**, Worm body in ileum. **C**, *Taenia saginata* washed down to ascending colon. There is no worm body in ileum. **D**, Tapeworm has reached rectum.

body. Expelled worms were alive with intact scoleces and showed active waving motion in all cases. Total dose of Gastrografin was 250–500 ml. Initial dose was 100–200 ml and the additional dose was 100–300 ml. By administration of less than 300 ml of Gastrografin, all tapeworms descended from the jejunum to the colon. The total time required for expulsion after administration of Gastrografin was 35 min in two cases and 40 min in two cases. No adverse effects were noted during or after the treatment.

Discussion

Bithionol, niclosamide, Paromomycin [1, 2], quinacrine, and mebendazole [3] are well known as antiparasitics. With these drugs, the antiparasitic effect cannot always be controlled sufficiently due to the general condition of the host and the parasitic condition of the cestodes. Moreover, as serious adverse reactions are known to accompany some antiparasitics, the use of laxatives is mandatory. Bithionol, niclosam-

ide, and Paromomycin have a destructive effect on the parasite body, so they are not suitable for expulsion of *Taenia solium*, which may cause cysticercosis. Also, it is difficult to confirm the existence of a cestode scolex because of the destruction of the body. Therefore, a cure can be confirmed only if a cestode does not recur from a remaining scolex. This entails a follow-up period of several months.

The method of expelling cestodes with a duodenal tube has been reported with a high cure rate [4]. This method uses the phenomenon that parasites are expelled at high temperature and under exposure to large doses of cathartic salts. Damaso de Rivas [4] used a mixture of 30% magnesium sulfate aqueous solution and glycerin, plus a physiologic saline solution, warmed to 45°–47°C, in the duodenum. However, Kihara et al. [5] reported that they used 42°C physiologic saline solution, because damage to the duodenal mucosa of the host was observed when using the higher temperatures. As compared with oral administration, duodenal instillation is preferable because a large amount of the drug in high concentration can act on the parasite body in a more massive and direct manner. However, with the method of Kihara et al. [5], cestodes can be found only by a barium study, which disturbs the subsequent therapy.

By administration of Gastrografin (250–500 ml), we observed cestode bodies fluoroscopically and succeeded in expelling them in all cases. This method is easier and causes less patient distress than the method of Kihara et al. [5]. As previously mentioned, a parasite body was found by the first administration of 100–200 ml of Gastrografin. Then the body was observed to be free from the jejunal wall. Additional Gastrografin (100–300 ml) was administered, and we observed the body descending from the jejunum to the colon with the peristalsis of small intestine. In one case, the body began to descend after the first administration of Gastrografin. In another case, the excessive administration of 500 ml was carried out to confirm the absence of multiple body sections. The actual dosage needed for expulsion seems to be 200–300 ml. The expelled worm showed an active wave motion and none of the scoleces of the cestodes was injured, so cure could be determined immediately.

Gastrografin is a 76% solution of diatrizoate, a water-soluble contrast medium and a three-iodine compound. It is a mixture of 66% meglumine salt solution and 10% sodium salt solution. It is a hypertonic solution with a specific gravity of 1.416–1.420, pH of 6.0–7.7, iodine content of 370 mg/ml, and osmotic pressure of 1900 mosmol/L. When Gastrografin is used for upper gastrointestinal series, diarrhea is often a result. This is thought to be caused by the transportation of water from the intestinal wall into the intestinal lumen by high osmotic pressure [6, 7]. This water causes an increase in intestinal contents. Another theory is that the Gastrografin directly stimulates the intestinal wall, which results in accelerated peristalsis of the intestine [8].

The expulsive effect of Gastrografin on the cestode is not clear, but it seems that a cathartic effect is one of the main mechanisms. The direct effect of Gastrografin on the cestode may also play a role in expulsion. It is presumed that stimulation of the scolex by a hypertonic solution containing iodine may cause release of the cestode body from the intestinal wall, and that acceleration of peristalsis and the increase of intestinal contents may cause expulsion of the cestode.

REFERENCES

1. Yoshida Y, Matsuo K, Ikai T, et al. Treatment of *Diphyllobothrium latum* and *Taenia saginata* infections with aminosidine. *Jpn J Antibiot* **1979**;32:1178–1182
2. Tongu Y, Aji T, Fukuda T, Itano K, Inatomi S. Ultrastructural changes in *Diphyllobothrium latum* from man treated with paromomycin sulfate. *Jpn J Antibiot* **1982**;35:2126–2130
3. Arambulo PV III, Cabrera BD, Cabrera MG. The use of mebendazole in the treatment of *Taenia saginata* taeniasis in an endemic area in the Philippines. *Acta Trop* (Basel) **1978**;35:281–286
4. Damaso de Rivas. Intestinal parasitism, diagnosis and treatment. *Am J Trop Med* **1932**;12:477–492
5. Kihara T, Kobayashi R, Tsuji O, Okazaki S, Kosaka K. Studies on large tapeworm. 3: Treatment of large tapeworm infections in man. *Nippon Shokakibyo Gakkai Zasshi* **1973**;70:196–207
6. Harris PD, Neuhauser EBD, Gerth R. The osmotic effect of water soluble contrast media on circulating plasma volume. *AJR* **1964**;91:694–698
7. Wood BP, Katzberg RW, Ryan DH, Karch FE. Diatrizoate enemas: fact and fallacies of colonic toxicity. *Radiology* **1978**; 126:441–444
8. Lutzger LG, Factor SM. Effects of some water-soluble contrast media on the colonic mucosa. *Radiology* **1976**;118: 545–548