



## Special article

# Japanese Classification of Gastric Carcinoma - 2nd English Edition -

Japanese Gastric Cancer Association

Association office, First Department of Surgery, Kyoto Prefectural University of Medicine, Kawaramachi, Kamigyo-ku, Kyoto, 602-0841, Japan

### Preface

The first edition of the General Rules for Gastric Cancer Study was published by the Japanese Research Society for Gastric Cancer (JRSGC) in 1963. The first English edition [1] was based on the 12th Japanese edition and was published in 1995. In 1997, the JRSGC was transformed into the Japanese Gastric Cancer Association and this new association has maintained its commitment to the concept of the Japanese Classification. This second English edition was based on the 13th Japanese edition [2].

The aim of this classification is to provide a common language for the clinical and pathological description of gastric cancer and thereby contribute to continued research and improvements in treatment and diagnosis.

**Key words:** gastric cancer, classification, manual, surgery, pathology

### I. General principles

Findings are recorded using the upper case letters T (depth of tumor invasion), N (lymph node metastasis), H (hepatic metastasis), P (peritoneal metastasis) and M (distant metastasis). The extent of each finding is expressed by Arabic numerals following each upper case letter. “X” is used in unknown cases. Four categories of findings, namely Clinical, Surgical, Pathological, and Final Findings, are identified using the lower case “c”,

“s”, “p”, and “f”, respectively, before each upper case letter. The “f” of Final Findings may be omitted. Any findings once established must remain unchanged.

**Example:** pT3, pN2, sH0, sP0, sM0, f Stage IIIB (or Stage IIIB)

In the case of multiple simultaneous primary tumors, the tumor with the deepest invasion of the gastric wall should be used for staging purposes.

**Clinical Findings :** Any findings during diagnostic evaluation, including diagnostic laparoscopy, are defined as Clinical Findings. These are recorded as cT2, cN1, cM0, cStage II.

**Surgical Findings :** Any findings during surgery, including frozen sections, cytology, and macroscopic examination of the resected specimens, are defined as Surgical Findings. Results of therapeutic laparoscopy are included in Surgical Findings.

**Pathological Findings :** Any findings based on microscopic examination of materials obtained by endoscopic, laparoscopic or surgical resection are defined as Pathological Findings.

**Final Findings :** Comprehensive findings based on Clinical, Surgical and Pathological Findings are

**Table 1.** Principles of recording

Clinical Findings (c)	Surgical Findings (s)	Pathological Findings (p)	Final Findings (f)
Physical examination Diagnostic imaging Endoscopy and biopsy <i>Diagnostic</i> laparoscopy, biopsy and cytology Biochemical and/or biological examination Others (genetic studies,etc)	Operative findings Intraoperative diagnostic imaging Intraoperative cytology Frozen sections	Pathological examination of materials obtained only by surgical, endoscopic, or laparoscopic <i>resection</i>	Comprehensive summary of findings based on Clinical, Surgical and Pathological Findings.

defined as Final Findings. When there is conflict between Surgical and Pathological Findings, the Pathological Findings take precedence.

## II. Findings

### A Primary lesions

#### 1. Number and size of lesions

The two greatest dimensions should be recorded for each lesion.

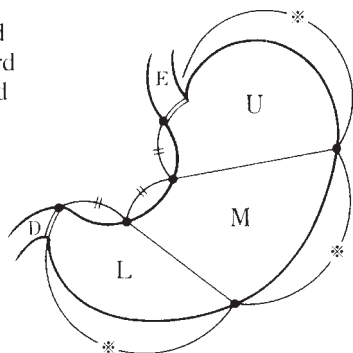
#### 2. Tumor Location

##### a) Three parts of the stomach

The stomach is anatomically divided into three portions; the upper (U), middle (M), and lower (L) parts (Fig.1). If more than one portion is involved, all involved portions should be described in order of degree of involvement, the first indicating the portion in which the bulk of the tumor is situated, e.g. LM or UML. Tumor extension into the esophagus or the duodenum is recorded as E or D, respectively.

**Fig. 1.** Three portions of the stomach

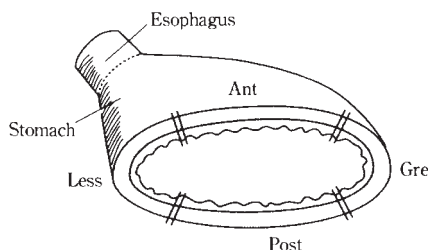
U : Upper third  
M : Middle third  
L : Lower third  
E : Esophagus  
D : Duodenum



Three portions are defined by subdividing both lesser and greater curvatures into 3 equal lengths.

**Fig. 2.** Four equal parts of the gastric circumference

Less : Lesser curvature  
Gre : Greater curvature  
Ant : Anterior wall  
Post : Posterior wall



##### b) Cross-sectional parts of the stomach

The cross-sectional circumference of the stomach is divided into four equal parts; the lesser (Less) and greater curvatures (Gre), and the anterior (Ant) and posterior walls (Post) (Fig 2). Circumferential involvement is recorded as Circ.

##### c) Carcinoma in the remnant stomach

The following three items should be recorded using hyphens.

- The reason for the previous gastrectomy: benign disease (B), malignant disease (M), or unknown (X).
- The interval between the previous gastrectomy and the current diagnosis in years, (unknown : X).
- Tumor location in the remnant stomach: anastomotic site (A), gastric suture line (S), other site in the stomach (O) or total remnant stomach (T). Extension into the esophagus (E), duodenum (D), or jejunum (J) should be recorded.

**Examples :** B-20-S; M-09-AJ

If available, the extent of resection and the reconstruction method of the previous gastrectomy are recorded.

### 3. Macroscopic types

Macroscopic types of primary tumor should be recorded together with T classification (Fig. 3, 4).

Example of endoscopic diagnosis : cType 0 IIa, T1

Type 0 : Superficial, flat tumors with or without minimal elevation or depression.

Type 0 I : Protruded type  
Type 0 IIa : Superficial elevated type  
Type 0 IIb : Flat type  
Type 0 IIc : Superficial depressed type  
Type 0 III : Excavated type

Type 1 : Polypoid tumors, sharply demarcated from the surrounding mucosa, usually attached on a wide base.

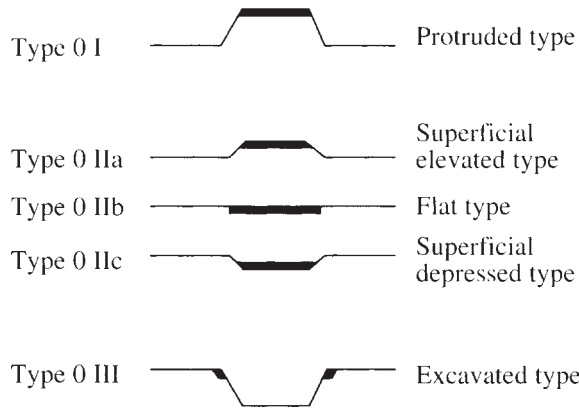
Type 2 : Ulcerated carcinomas with sharply demarcated and raised margins.

Type 3 : Ulcerated carcinomas without definite limits, infiltrating into the surrounding wall.

Type 4 : Diffusely infiltrating carcinomas in which ulceration is usually not a marked feature.

Type 5 : Non-classifiable carcinomas that cannot be classified into any of the above types.

**Fig. 3.** Subtypes of Type 0

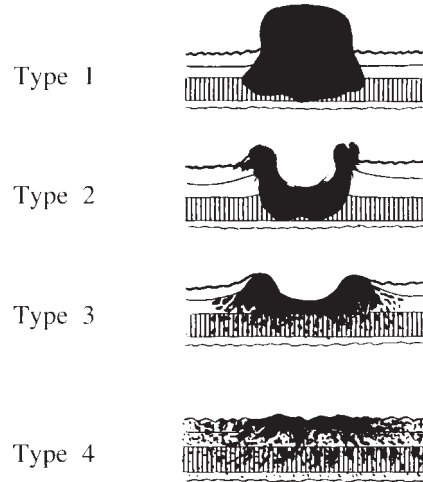


**Note 1 :** In the combined superficial types, the type occupying the largest area should be described first, followed by the next type, e.g. IIc + III.

**Note 2 :** Type 0 I and Type 0 IIa are distinguished as follows:

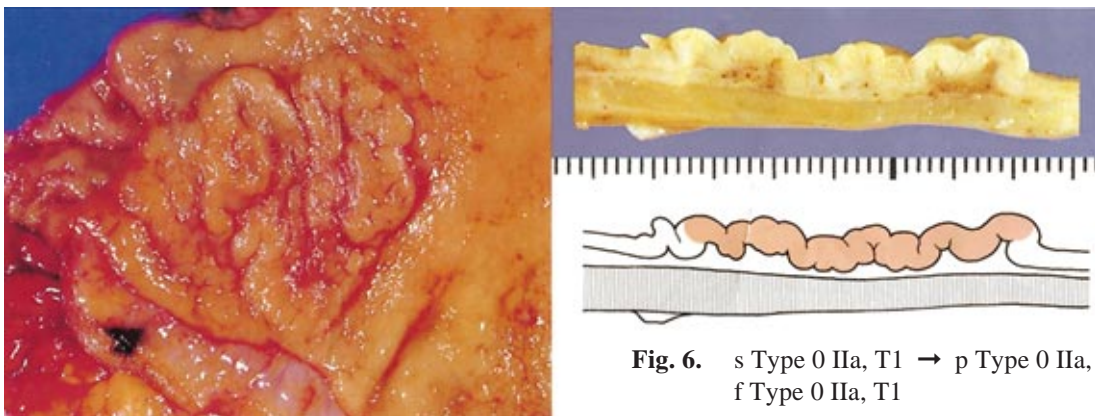
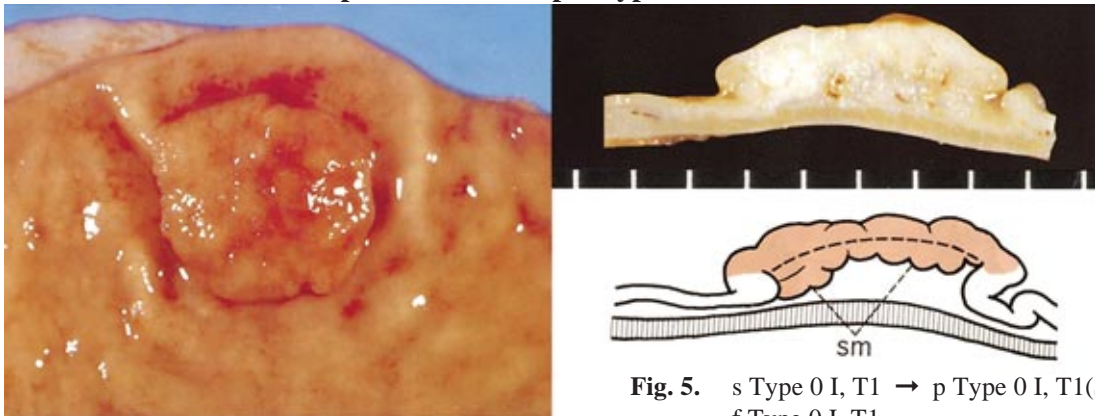
- Type 0 I : The lesion has a thickness of more than twice that of the normal mucosa.
- Type 0 IIa : The lesion has a thickness up to twice that of the normal mucosa.

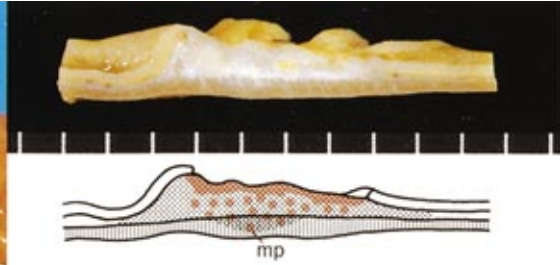
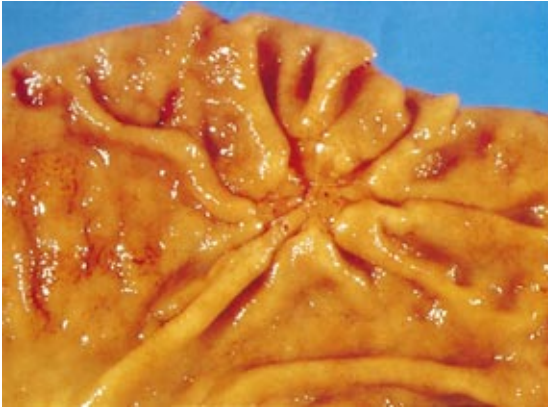**Fig. 4.** Types of 1, 2, 3, and 4



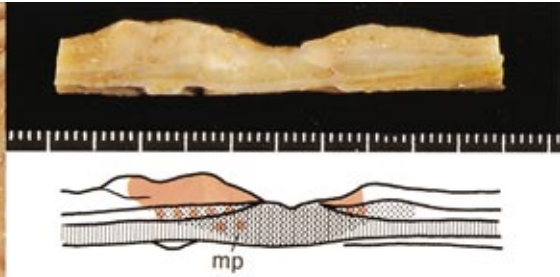
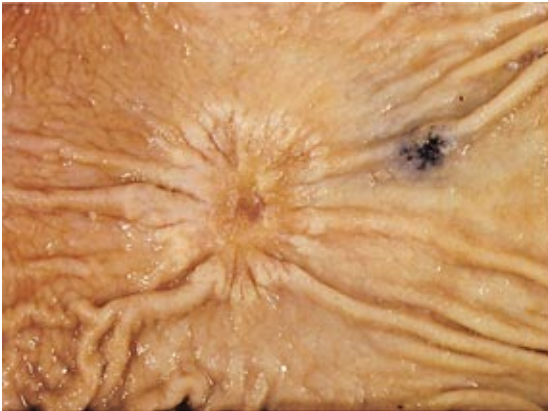**Note :** The classification of early gastric cancer was established by the Japanese Endoscopic Society for the description of T1 tumors. In this manual, all macroscopically superficial flat tumors resembling early gastric cancer are described as sub-types of type 0, irrespective of histological depth of invasion.

**Examples of Macroscopic Type Classification**

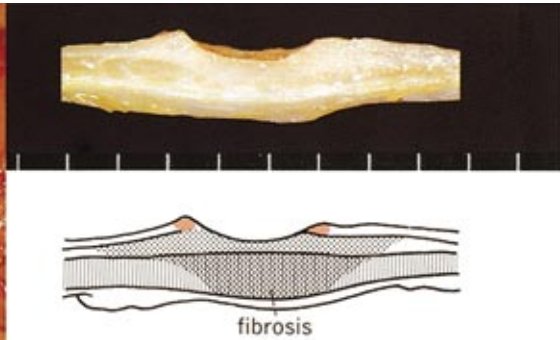
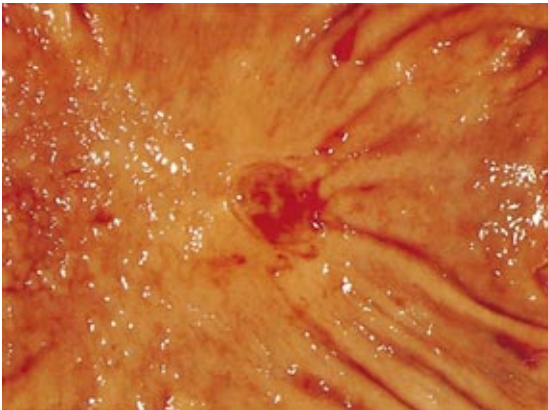




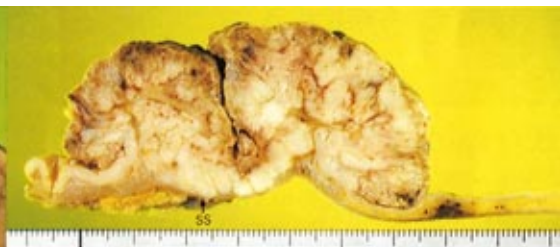
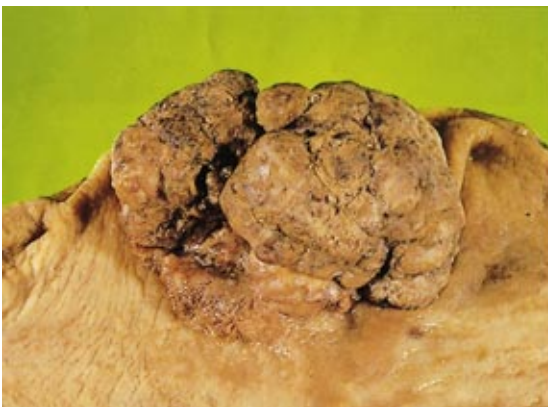**Fig. 7.** s Type 0 IIc, T2 → p Type 0 IIc, T2(MP) → f Type 0 IIc, T2



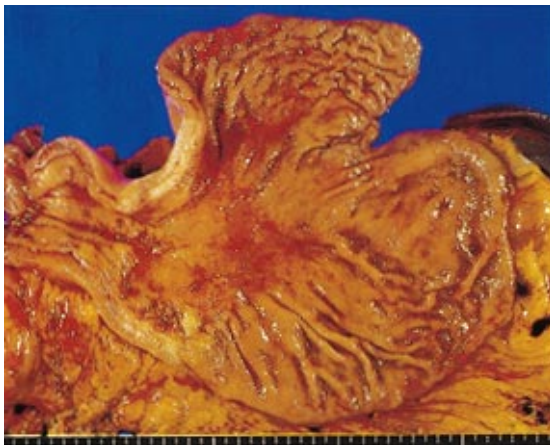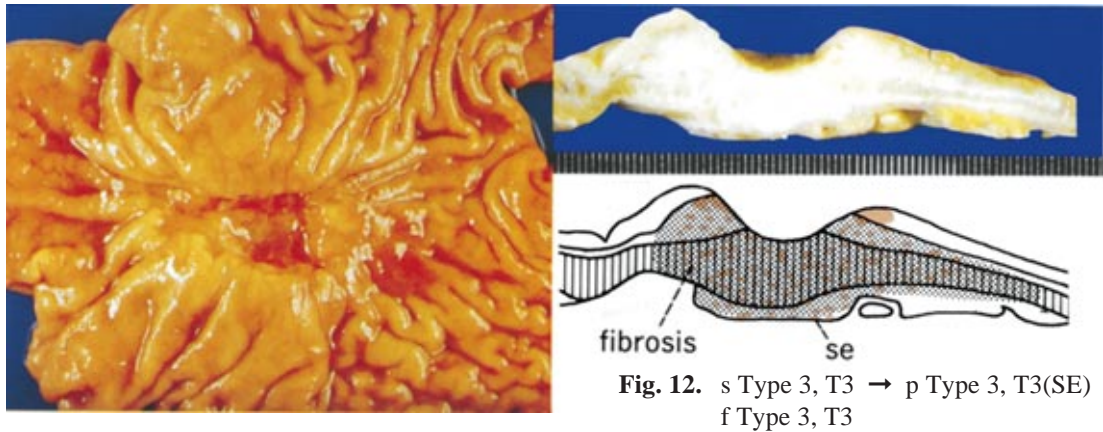
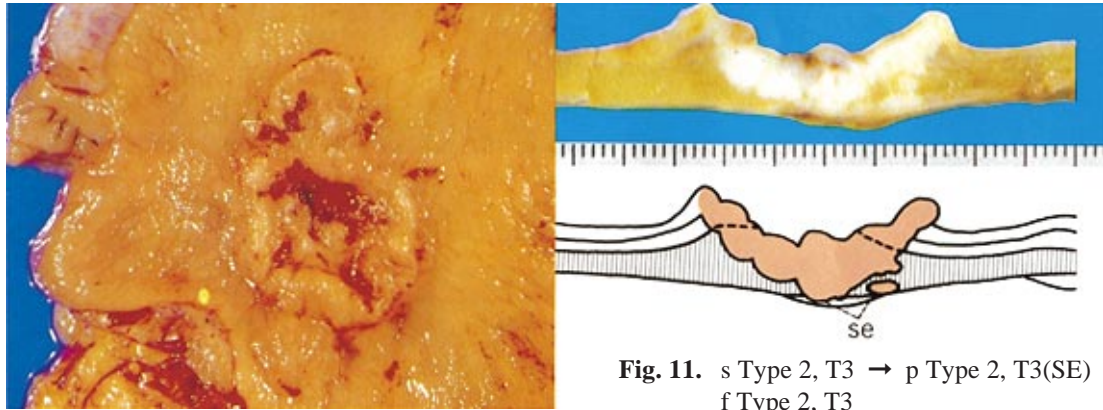
**Fig. 8.** s Type 0 IIc+III, T2 → p Type 0 IIc+III, T2(MP) → f Type 0 IIc+III, T2



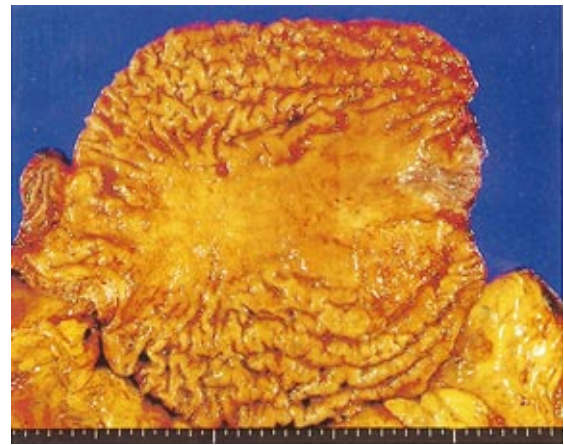**Fig. 9.** s Type 0 III, T1 → p Type 0 III, T1(M) → f Type 0 III, T1



**Fig. 10.** s Type 1, T2 → p Type 1, T2(SS) → f Type 1, T2



**Fig. 13.** s Type 4, T3 → p Type 4, T3(SE) → f Type 4, T3



**Fig. 14.** s Type 4, T3 → p Type 4, T3(SE) → f Type 4, T3

#### 4. Depth of tumor invasion (T)

Depth of tumor invasion is recorded using T-classification. Anatomical levels of invasion of the gastric wall are also recorded as follows.

- T1 : Tumor invasion of mucosa and / or muscularis mucosa (M) or submucosa (SM)
- T2 : Tumor invasion of muscularis propria (MP) or subserosa (SS)
- T3 : Tumor penetration of serosa (SE)
- T4 : Tumor invasion of adjacent structures (SI)
- TX : Unknown

A tumor may penetrate muscularis propria with extension into the greater and lesser omentum, (or occasionally the gastrocolic or gastrohepatic ligaments) without perforation of the visceral peritoneum covering these structures. In this case, the tumor is classified as T2. If there is perforation of the visceral peritoneum, the tumor is classified as T3.

Invasion of greater and lesser omenta, esophagus, and duodenum is not regarded as T4 disease. Tumors with intramural extension to the esophagus or duodenum are classified by the depth of greatest invasion in any of these sites, including the stomach.

## B. Metastatic lesions

### 1. Lymph node metastasis

#### a) Regional lymph nodes

The regional lymph nodes of the stomach are classified into stations numbered as in Table 2 and Fig. 15 - 18.

#### b) Grouping (Compartments) of lymph nodes

The regional lymph nodes are classified into three groups depending upon the location of the primary tumor (Table 3). The classification of No. 19 - No. 112 is modified when the tumor also invades the esophagus (E+). This grouping system is based on the results of studies of lymphatic flow at various tumor sites, together with the observed survival associated with metastasis at each nodal station.

**Note 1 :** Occasionally, perigastric nodes can be classified as distant nodes ("M" in Table 3) because in certain circumstances involvement is associated with such a poor outcome it is regarded as evidence of distant metastasis (M1).

**Note 2 :** In carcinoma of the remnant stomach with gastrojejunostomy, lymph nodes along the jejunum are classified as No. J1, and the lymph nodes in the jejunal mesentery are No. J2 (except for No. 14a and 14v). If the tumor invades the jejunum, J1 nodes are classified as Group 1, and J2 nodes as Group 2. If there is no jejunal invasion, J1 nodes are classified as Group 2, and J2 nodes as Group 3.

#### c) Extent of lymph node metastasis (N)

N0 : No evidence of lymph node metastasis

N1 : Metastasis to Group 1 lymph nodes, but no metastasis to Groups 2 or 3 lymph nodes

N2 : Metastasis to Group 2 lymph nodes, but no metastasis to Group 3 lymph nodes

N3 : Metastasis to Group 3 lymph nodes

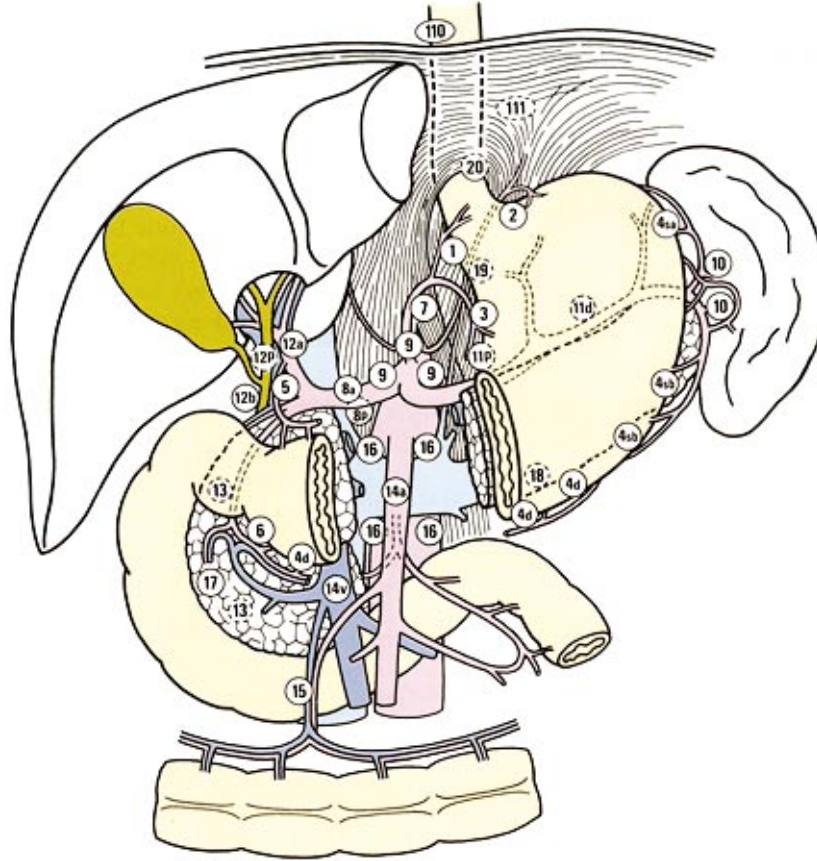
NX: Unknown

**Table 2.** Regional lymph nodes

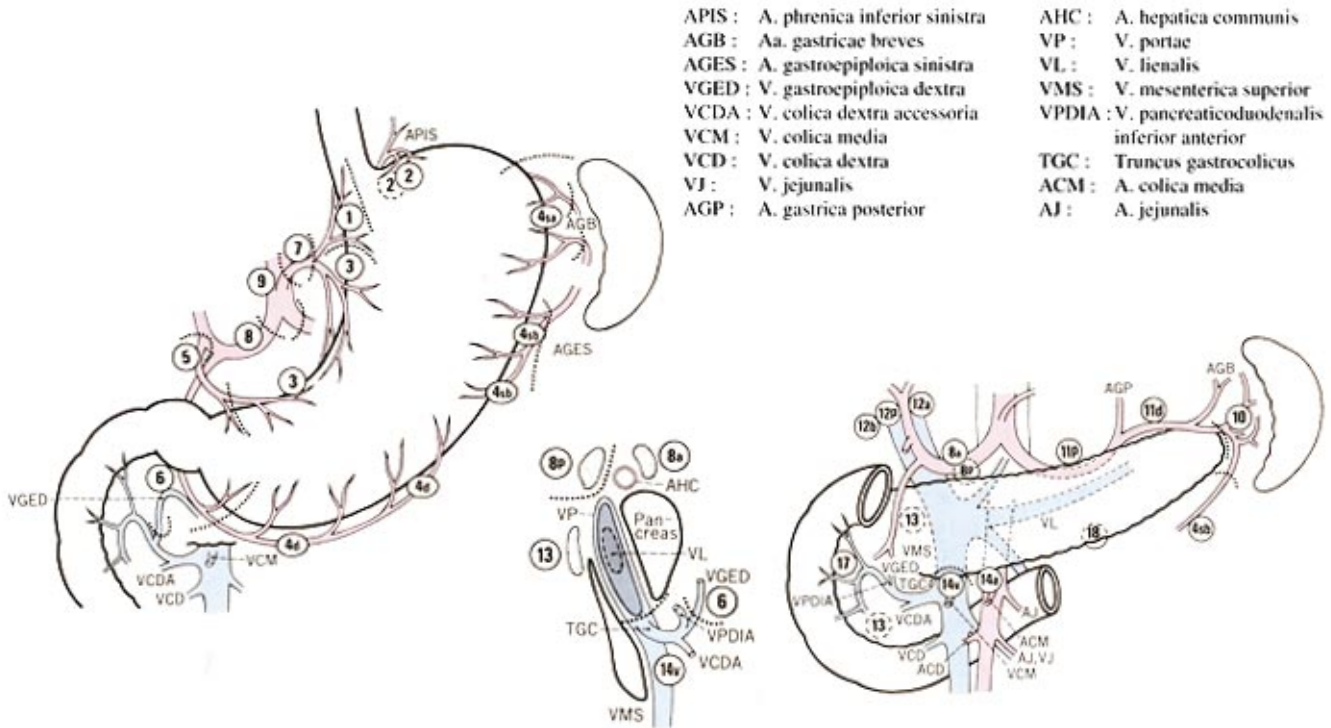
No. 1	Right paracardial LN
No. 2	Left paracardial LN
No. 3	LN along the lesser curvature
No. 4sa	LN along the short gastric vessels
No. 4sb	LN along the left gastroepiploic vessels
No. 4d	LN along the right gastroepiploic vessels
No. 5	Suprapyloric LN
No. 6	Infrapyloric LN
No. 7	LN along the left gastric artery
No. 8a	LN along the common hepatic artery (Anterosuperior group)
No. 8p	LN along the common hepatic artery (Posterior group)
No. 9	LN around the celiac artery
No. 10	LN at the splenic hilum
No. 11p	LN along the proximal splenic artery
No. 11d	LN along the distal splenic artery
No. 12a	LN in the hepatoduodenal ligament (along the hepatic artery)
No. 12b	LN in the hepatoduodenal ligament (along the bile duct)
No. 12p	LN in the hepatoduodenal ligament (behind the portal vein)
No. 13	LN on the posterior surface of the pancreatic head
No. 14v	LN along the superior mesenteric vein
No. 14a	LN along the superior mesenteric artery
No. 15	LN along the middle colic vessels
No. 16a1	LN in the aortic hiatus
No. 16a2	LN around the abdominal aorta (from the upper margin of the celiac trunk to the lower margin of the left renal vein)
No. 16b1	LN around the abdominal aorta (from the lower margin of the left renal vein to the upper margin of the inferior mesenteric artery)
No. 16b2	LN around the abdominal aorta (from the upper margin of the inferior mesenteric artery to the aortic bifurcation)
No. 17	LN on the anterior surface of the pancreatic head
No. 18	LN along the inferior margin of the pancreas
No. 19	Infradiaphragmatic LN
No. 20	LN in the esophageal hiatus of the diaphragm
No. 110	Paraesophageal LN in the lower thorax
No. 111	Supradiaphragmatic LN
No. 112	Posterior mediastinal LN

Stations No. 11 and 12 were subdivided for this edition.

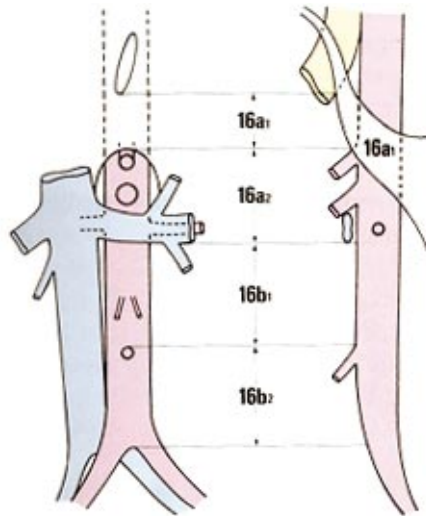
**Fig. 15.** Lymph node station numbers



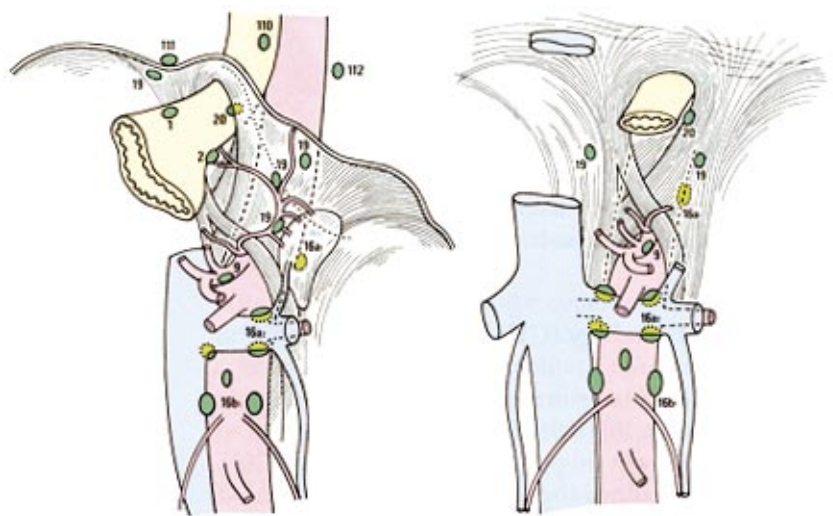
**Fig. 16.** Location of lymph node stations



**Fig. 17.** Location of lymph nodes around the abdominal aorta



**Fig. 18.** Location of lymph nodes in the esophageal hiatus, and infradiaphragmatic and paraaortic regions



**Table 3.** Lymph node groups (Compartments 1 - 3) by location of tumor

Location		LMU / MUL MLU / UML	LD / L	LM / M / ML	MU / UM	U	E+
No. 1	rt paracardial	1	2	1	1	1	
No. 2	lt paracardial	1	M	3	1	1	
No. 3	lesser curvature	1	1	1	1	1	
No. 4sa	short gastric	1	M	3	1	1	
No. 4sb	lt gastroepiploic	1	3	1	1	1	
No. 4d	rt gastroepiploic	1	1	1	1	2	
No. 5	suprapyloric	1	1	1	1	3	
No. 6	infrapyloric	1	1	1	1	3	
No. 7	lt gastric artery	2	2	2	2	2	
No. 8a	ant comm hepatic	2	2	2	2	2	
No. 8b	post comm hepatic	3	3	3	3	3	
No. 9	celiac artery	2	2	2	2	2	
No. 10	splenic hilum	2	M	3	2	2	
No. 11p	proximal splenic	2	2	2	2	2	
No. 11d	distal splenic	2	M	3	2	2	
No. 12a	lt hepatoduodenal	2	2	2	2	3	
No. 12b,p	post hepatoduod	3	3	3	3	3	
No. 13	retropancreatic	3	3	3	M	M	
No. 14v	sup mesenteric v.	2	2	3	3	M	
No. 14a	sup mesenteric a.	M	M	M	M	M	
No. 15	middle colic	M	M	M	M	M	
No. 16a1	aortic hiatus	M	M	M	M	M	
No. 16a2,b1	paraaortic, middle	3	3	3	3	3	
No. 16b2	paraaortic, caudal	M	M	M	M	M	
No. 17	ant pancreatic	M	M	M	M	M	
No. 18	inf pancreatic	M	M	M	M	M	
No. 19	infradiaphragmatic	3	M	M	3	3	2
No. 20	esophageal hiatus	3	M	M	3	3	1
No. 110	lower paraesophag	M	M	M	M	M	3
No. 111	supradiaphragmatic	M	M	M	M	M	3
No. 112	post mediastinal	M	M	M	M	M	3

M : lymph nodes regarded as distant metastasis

E+ : lymph node stations re-classified in cases of esophageal invasion



## 2. Liver metastasis (H)

H0 : No liver metastasis  
 H1 : Liver metastasis  
 HX : Unknown

## 3. Peritoneal Metastasis (P)

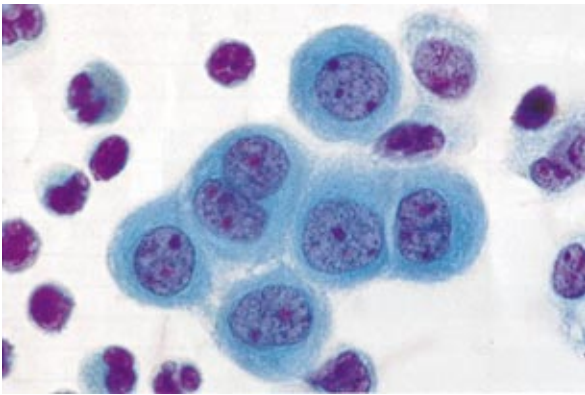
P0 : No peritoneal metastasis  
 P1 : Peritoneal metastasis  
 PX : Unknown

## 4. Peritoneal cytology (CY)

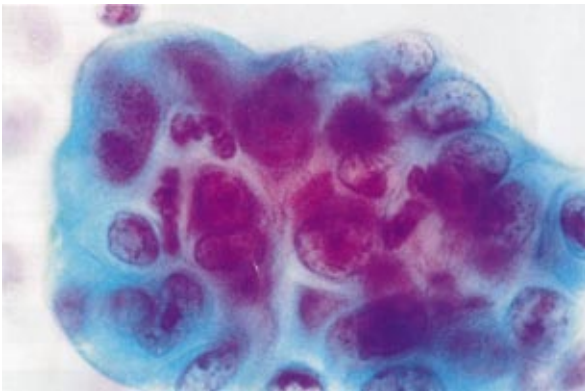
CY0 : Benign / indeterminate cells on peritoneal cytology (Fig. 19)  
 CY1 : Cancer cells on peritoneal cytology (Fig. 20)  
 CYX : Peritoneal cytology was not performed.

**Note :** "Suspicious of malignancy" in cytological diagnosis should be classified as CY0.

**Fig. 19.** Cytology CY0 (Papanicolaou staining)



**Fig. 20.** Cytology CY1 (Papanicolaou staining)



## 5. Other distant metastases (M)

M0 : No other distant metastases, (although peritoneal, liver, or cytological metastases may be present)  
 M1 : Distant metastases other than the peritoneal, liver, or cytological metastases  
 MX : Unknown

The category M1 should be specified according to the following notations :

LYM : Lymph nodes  
 PUL : Pulmonary  
 PLE : Pleura  
 MAR : Bone marrow  
 OSS : Osseous  
 BRA : Brain  
 MEN : Meninges  
 SKI : Skin  
 OTH : Others

## C. Stage

**Table 4.** Stage grouping

	N0	N1	N2	N3
T1	IA	IB	II	IV
T2	IB	II	IIIA	
T3	II	IIIA	IIIB	
T4	IIIA	IIIB		
H1, P1, CY1, M1				

## III. Surgical treatment

### 1. Approaches

Intraluminal endoscopy  
 Laparoscopy  
 Laparotomy  
 Thoraco-laparotomy  
 Others

### 2. Operative procedures

Mucosectomy  
 Wedge resection  
 Segmental resection  
 Proximal gastrectomy  
 Pylorus preserving gastrectomy  
 Distal gastrectomy  
 Total gastrectomy

Other resections  
 Bypass without resection  
 Exploratory (non-therapeutic) laparotomy  
 Gastrostomy or other stoma formation  
 Other palliative operations

### 3. Combined resection

All structures resected together with the main tumor should be recorded, e.g. spleen, liver, pancreas, transverse colon, transverse mesocolon, gallbladder, adrenal gland, ovary, etc. Resection of the greater or lesser omentum, the anterior sheet of the transverse mesocolon, the abdominal esophagus, and the first portion of the duodenum, are not included in this category.

### 4. Involvement of the resection margins

#### a) Proximal margin (PM)

PM(-) : No involvement of the proximal margin  
 PM(+) : Involvement of the proximal margin  
 PMX : Unknown

#### b) Distal margin (DM)

DM(-) : No involvement of the distal margin  
 DM(+) : Involvement of the distal margin  
 DMX : Unknown

### 5. Lymph node dissection (D)

D0 : No dissection or incomplete dissection of the Group 1 nodes  
 D1 : Dissection of all the Group 1 nodes  
 D2 : Dissection of all the Group 1 and Group 2 nodes  
 D3 : Dissection of all the Group 1, Group 2 and Group 3 nodes

Please refer to Table 3 for details.

### 6. Curative potential of gastric resection (Resection)

The curative potential of gastric resection should be evaluated based on both Surgical and Final Findings as follows:

Resection A : No residual disease with high probability of cure (see below)  
 Resection B : No residual disease but not fulfilling criteria for "Resection A"  
 Resection C : Definite residual disease

Resection A implies resections satisfying all of the

following conditions : T1 or T2; N0 treated by D1, 2, 3 resection or N1 treated by D2, 3 resection; M0, P0, H0, CY0 and proximal and distal margins >10 mm.

## IV. Handling of the resected specimen and description of histological findings

### A. Surgical specimens

#### 1. Measurement of lesions and fixation

After gross inspection and measurement of any serosal tumor involvement (Fig. 21), the stomach is, in general, opened along the greater curvature. On examination from the mucosal side, the tumor size and the length of the proximal and distal resection margins are measured (Fig. 21).

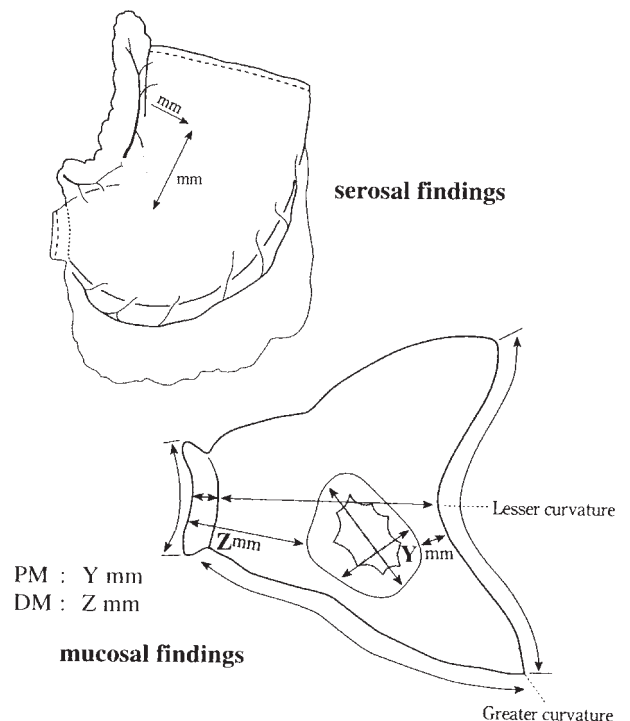
After dissection of the lymph nodes from the specimen, the stomach is placed on a flat board with the mucosal side up, pinned at the edges with stainless steel pins, and fixed in a 15 - 20% formalin solution.

#### 2. Sectioning of the stomach

Firstly a section is taken along the lesser curvature as a reference line to assess background changes.

In Type 0 superficial tumors, a set of sections parallel to the reference line should be made (Fig. 22). In advanced tumors, the area of deepest invasion should be sectioned parallel to the reference line. If there is

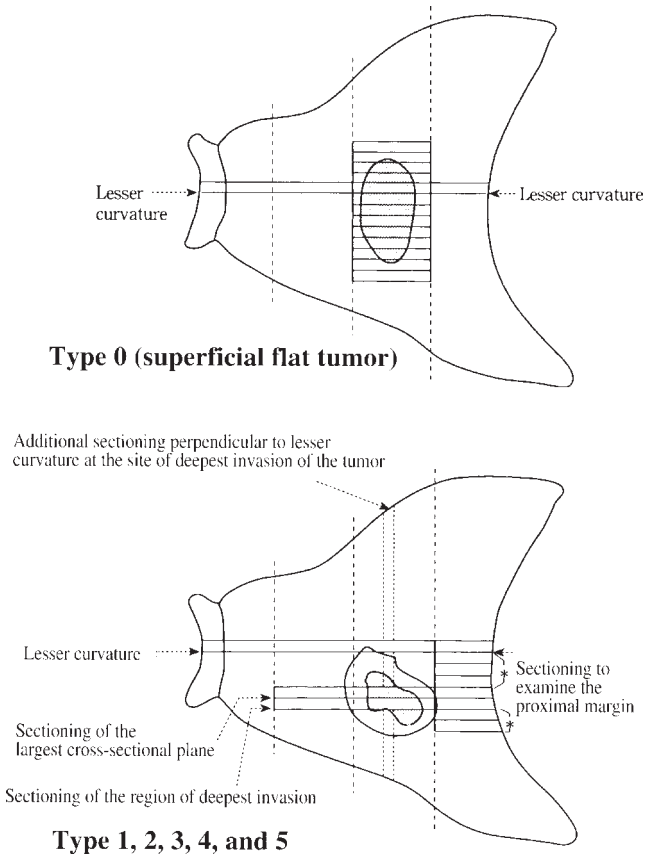
**Fig. 21.** Measurement of the lesion



concern about tumor margins, additional sections should be taken (Fig. 22).

In multiple tumors or tumors of unusual configuration, suitable sectioning to obtain accurate findings must be devised on a case-by-case basis. The carcinoma in a remnant stomach should be sectioned taking into account its relationship to the suture and anastomosis lines.

**Fig. 22.** Sectioning of the stomach resected



### 3. Sectioning of lymph nodes

Each dissected lymph node should be studied individually. The plane of largest dimension of the node should be sectioned.

#### B. Histological Typing

The histological classification should be based on the predominant pattern of tumor.

##### 1. Common types

Papillary adenocarcinoma	(pap)
Tubular adenocarcinoma	
Well-differentiated type	(tub 1)
Moderately differentiated type	(tub 2)

##### Poorly differentiated adenocarcinoma

Solid type	(por 1)
Non-solid type	(por 2)
Signet-ring cell carcinoma	(sig)
Mucinous adenocarcinoma	(muc)

**Note 1:** Undifferentiated carcinoma combined with a small adenocarcinoma component should be classified as poorly differentiated adeno-carcinoma.

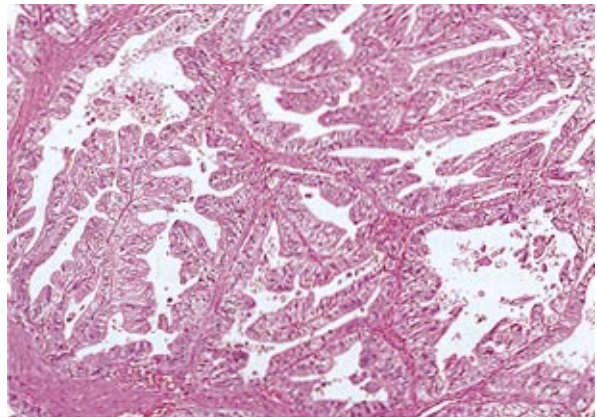
**Note 2:** In clinicopathological or epidemiological studies, papillary or tubular adenocarcinoma can be interpreted as differentiated or intestinal type, whereas "por" and "sig" can be regarded as the undifferentiated or diffuse type. Mucinous carcinoma can be interpreted as either intestinal or diffuse, depending upon the other predominant elements (pap, tub, por or sig).

Several examples are shown in Fig. 23 - 30.

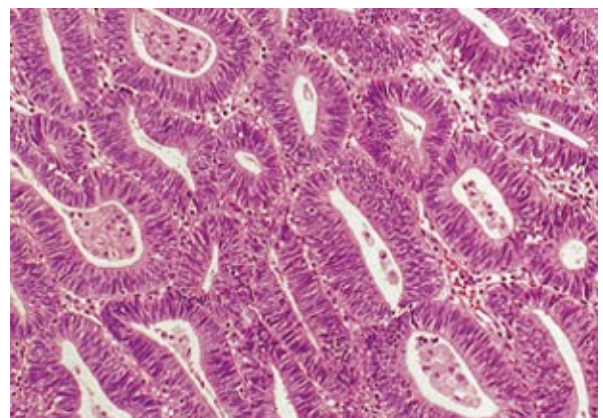
### 2. Special types

Adenosquamous carcinoma  
Squamous cell carcinoma  
Carcinoid tumor  
Other tumors

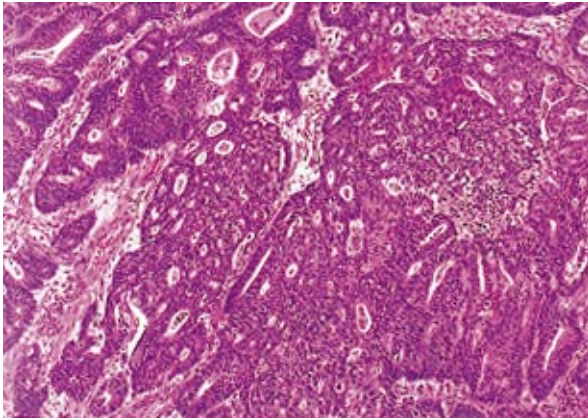
**Fig. 23.** Papillary adenocarcinoma (pap)



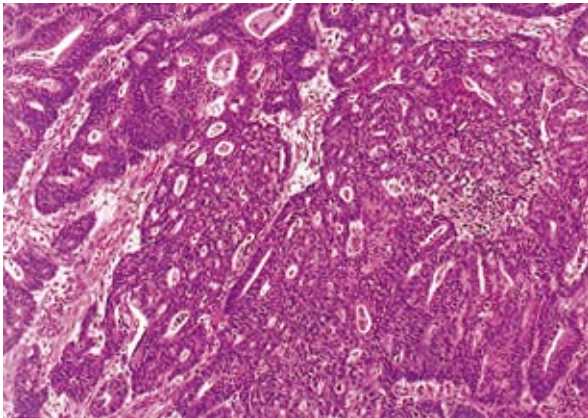
**Fig. 24.** Well-differentiated tubular adenocarcinoma (tub 1)



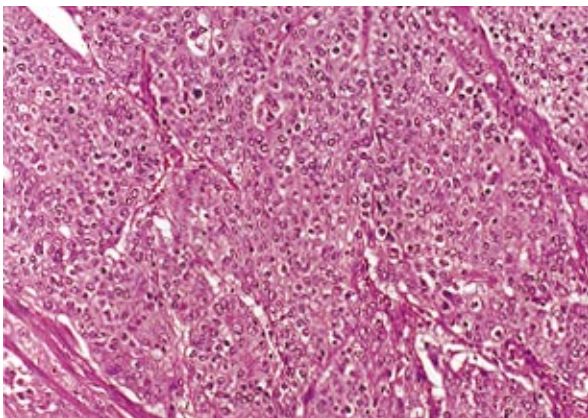
**Fig. 25.** Well-differentiated tubular adenocarcinoma (tub 1)



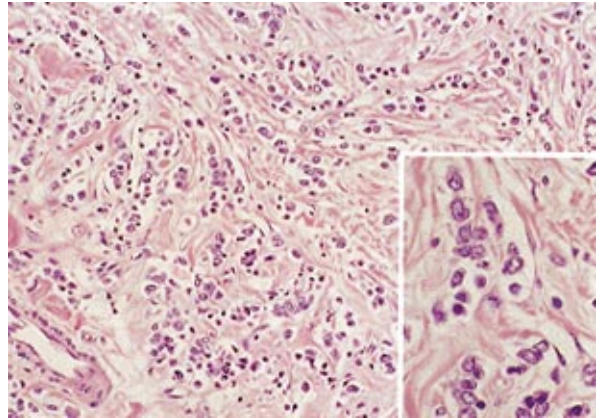
**Fig. 26.** Moderately differentiated tubular adenocarcinoma (tub 2)



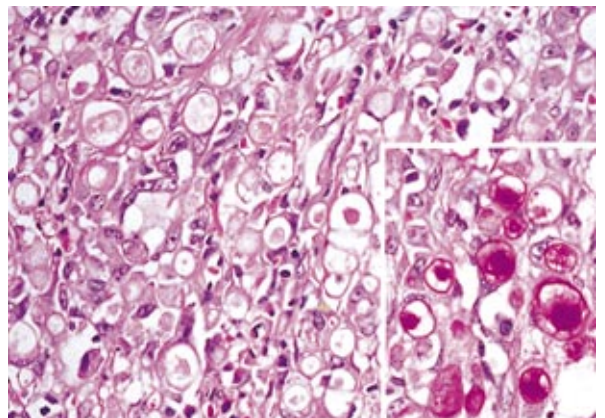
**Fig. 27.** Poorly differentiated adenocarcinoma, solid type (por 1)



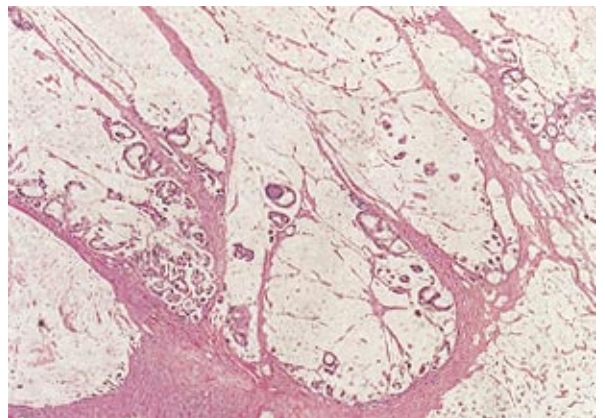
**Fig. 28.** Poorly differentiated adenocarcinoma, non-solid type (por 2)



**Fig. 29.** Signet-ring cell carcinoma (sig)  
Inset : PAS reaction



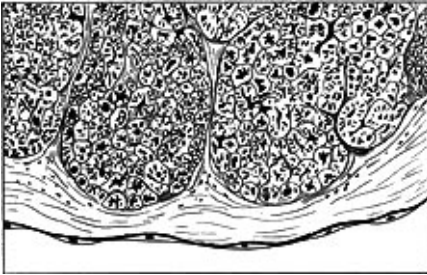
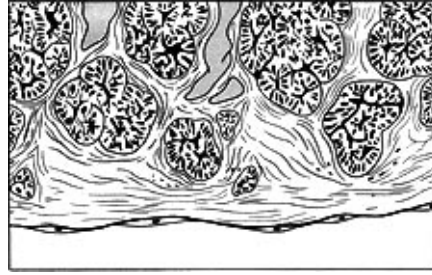
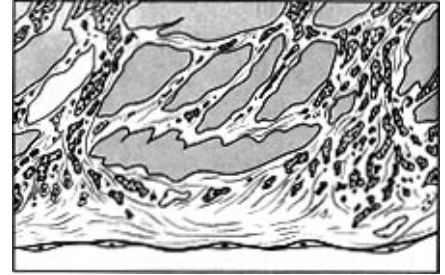
**Fig. 30.** Mucinous adenocarcinoma (muc)



### 3. Cancer-stroma relationship

med Medullary type ; Stroma is scanty.  
 sci Scirrhous type : Stroma is abundant.

int Intermediate type : The quantity of stroma is intermediate between those of the scirrhous type and medullary type.

**Fig. 31.** INF  $\alpha$ **Fig. 32.** INF  $\beta$ **Fig. 33.** INF  $\gamma$ 

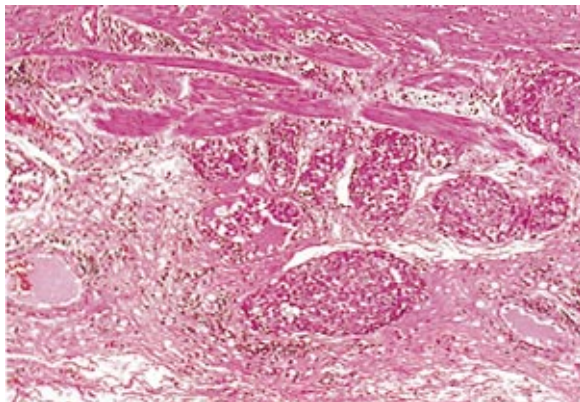
#### 4. Pattern of tumor infiltration into the surrounding tissue

The predominant pattern of infiltrating growth into the surrounding tissue should be classified as follows :

- INF  $\alpha$  (Infiltration Alpha) : The tumor shows expanding growth and a distinct border with the surrounding tissue (Fig. 31)
- INF  $\beta$  (Infiltration Beta) : This category is between Infiltration Alpha and Infiltration Gamma (Fig. 32)
- INF  $\gamma$  (Infiltration Gamma) : The tumor shows infiltrating growth and an indistinct border with the surrounding tissue (Fig. 33)

#### 5. Lymphatic invasion

- ly0 : No lymphatic invasion
- ly1 : Minimal lymphatic invasion
- ly2 : Moderate lymphatic invasion
- ly3 : Marked lymphatic invasion (Fig. 34)

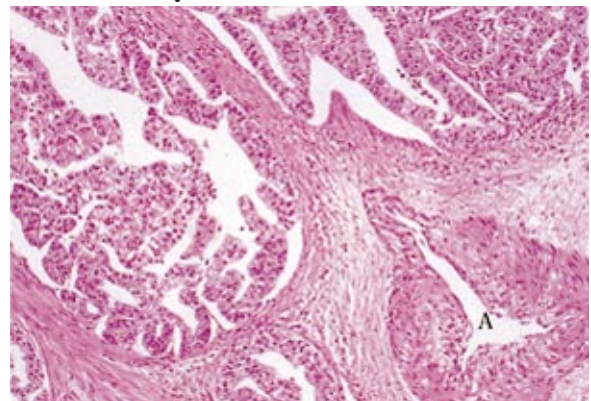
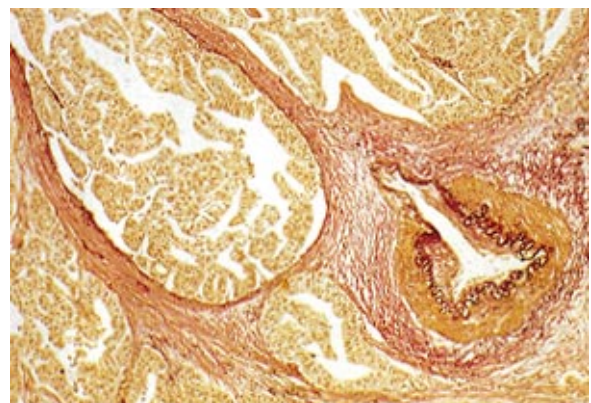
**Fig. 34.** Lymphatic invasion ly 3 (Subserosa)

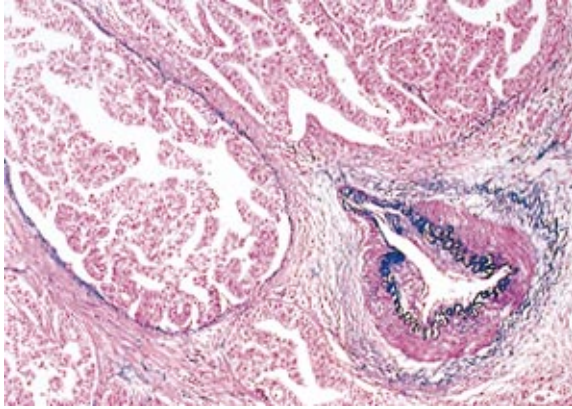
#### 6. Venous invasion

The degree of invasion within veins of the gastric wall should be classified as follows :

- v0 : No venous invasion
- v1 : Minimal venous invasion
- v2 : Moderate venous invasion
- v3 : Severe venous invasion

**Note :** Detection of venous invasion is often difficult by H&E staining (Fig. 35). Either Elastica staining (Fig. 36) or Victoria-blue H&E staining (Fig. 37) is recommended to identify venous structures.

**Fig. 35.** Venous invasion : upper left (H&E staining)  
A: artery**Fig. 36.** Venous invasion (Elastica staining)

**Fig. 37.** Venous invasion (Victoria-blue H&E staining)

## 7. Description of lymph node metastases

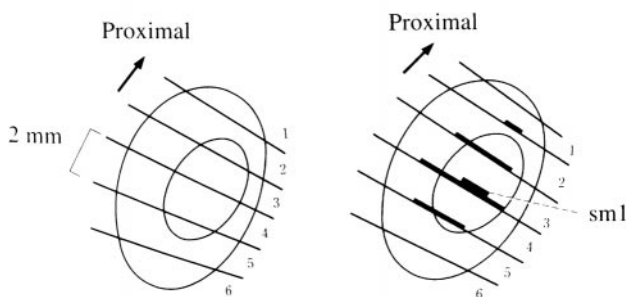
Overall metastatic rate (number of involved nodes / number of examined nodes) in all dissected nodes should be recorded, together with metastatic rate in each nodal station.

### C. Handling of mucosectomy specimens

#### 1. Measurement, fixation and sectioning

Specimens obtained by endoscopic or laparoscopic mucosal resection should be handled in the following manner: the specimen is spread out, pinned on a flat cork, and fixed in formalin solution. The size of specimen, the size and shape of the tumor, and the margins should be recorded on a schematic diagram. The proximal cut end is indicated by an arrow, if possible (Fig. 38).

Fixed materials should be sectioned serially at 2mm intervals parallel to a line that includes the closest resection margin of the specimen (Fig. 38)

**Fig. 38.** Sectioning of mucosectomy material

#### 2. Histological examination

The histological type and the size of the largest dimension of the tumor, the presence or absence of ulceration (UL), lymphatic invasion (ly) and venous

invasion (v) should be recorded. The depth of invasion (M, SM1, SM2) are determined and recorded only when the vertical margin (VM) is negative (SM1; submucosal invasion < 0.5mm, SM2; invasion  $\geq$  0.5mm).

### 3. Lateral margin (LM) and Vertical margin (VM)

The lateral margin (LM) should be assessed, and if LM(-), the length (mm) of the free margin or the number of normal tubules in the margin are recorded. Tumor extent, together with depth of invasion, should be recorded on a schematic diagram (Fig. 38).

LM(-) : No involvement of the mucosal lateral margin

LM(+) : Involvement of the mucosal lateral margin

LMX : Unknown

VM(-) : No involvement of the submucosal vertical margin

VM(+) : Involvement of the submucosal vertical margin

VMX : Unknown

### 4. Curative potential of mucosal resection (Resection)

Curative potential of endoscopic or laparoscopic mucosal resection (E) should be evaluated as follows. After resection in multiple fragments, curative potential is evaluated only on the completely reconstructed specimen.

Resection EA: Depth M (mucosa), histologically pap or tub, no ulcer or ulcer scar in the tumor, VM(-), no tumor cells within 1mm of LM\*, neither lymphatic nor venous invasion.

Resection EB: No margin involvement but not fulfilling criteria for "EA"

Resection EC: VM(+) and/or LM(+)

\* 1mm of LM approximately corresponds to the length of ten tubules.

#### Note

The Japanese 13th edition of the Classification of Gastric Carcinoma [2] contains the following additional information which has been omitted from this text for reasons of brevity:

- Group classification of gastric biopsy specimens
- Assessment of response to chemotherapy
- UICC TNM classification
- Instructions for statistical analysis
- Detailed technical and background information

## References

1. Japanese Research Society for Gastric Cancer. Japanese classification of gastric carcinoma, First English ed. Tokyo: Kanehara & Co., Ltd.; 1995
2. Japanese Gastric Cancer Association. Japanese classification of gastric carcinoma, 13th ed (in Japanese). Tokyo: Kanehara & Co., Ltd.; 1998

**Acknowledgements** The Association wishes to thank the following individuals for their valuable assistance.

- |                   |   |
|-------------------|---|
| Paul Hermanek     | University of Erlangen-Nürnberg,<br>Germany     |
| G. Bruce Mann     | University of Melbourne,<br>Australia           |
| David D. Kerrigan | University Hospital Aintree, Liverpool,<br>U.K. |

## Invitation for "International Members of the Japanese Gastric Cancer Association"

The **Japanese Gastric Cancer Association (JGCA)** accepts foreign specialists as *International members*. JGCA is principally a Japanese scientific association and the official language is Japanese, but the association continuously cooperates with the International Gastric Cancer Association (IGCA) to promote basic and clinical research. JGCA therefore accepts *international members* who are interested in joining its activities. The major areas of activity comprise:

### 1 Japanese Gastric Cancer Congress

The 71st annual Congress will be held in June 22-25, 1999, in Tokyo organized by Prof. Toshifusa Nakajima. We will accept English abstracts, English presentations, and English discussion by *International members*.

### 2 Publication of English journal "Gastric Cancer"

"Gastric Cancer" is the official journal of the IGCA and JGCA which will be published quarterly. The *International members* can receive the journal regularly and can send manuscripts to it.

### 3 Publication of new "Japanese Classification of Gastric Carcinoma"

JGCA will publish the 13th Japanese edition and the 2nd English edition in 1998.

### 4 Other activities

The *International members* can vote in the election of council members. They can purchase the "Report of Nationwide Registry of Gastric Cancer Patients" and "International Documentation System (CD-ROM, English version)" by as a discounted price.

### 5 Membership fee

The membership fee is 12,000 Yen for the first year, and 10,000 Yen in subsequent years. When an *International member* intends to join the IGCA, the IGCA membership fee will be reduced from US\$ 100 to US\$ 30 because the journal fee is already included in the JGCA membership fee.

Application forms will be sent from the following office by request.

**JGCA Association Office**  
c/o 1st Department of Surgery, Kyoto Prefectural University of Medicine  
Kawaramachi-Hirokoji, Kamigyo-ku, Kyoto, 602, Japan  
Fax: +81-75-251-5522