

# Is Lesion Size an Independent Indication for Endoscopic Resection of Biopsy-Proven Low-Grade Gastric Dysplasia?

Min Kyung Kim · Jae Young Jang ·  
Jung-Wook Kim · Jae-Jun Shim · Chang Kyun Lee ·  
Young Woon Chang · Bong Keun Choe

Received: 2 April 2013 / Accepted: 15 July 2013  
© Springer Science+Business Media New York 2013

## Abstract

**Background/Aim** The standard treatment for patients with gastric low-grade dysplasia (LGD) remains controversial, even though diagnosis of LGD is increasingly common as esophagogastroduodenoscopy becomes more available. The aim of this study was to identify a lesion size cut-off as an indication for endoscopic resection (ER) for patients with LGD.

**Results** We retrospectively reviewed 285 lesions initially diagnosed as LGD by endoscopic forceps biopsies (EFB) from 2007 to 2010 in Kyung Hee University Hospital, Seoul, Korea. All patients underwent ER. A total of 285 lesions from 257 patients were assessed. After ER, 239 LGD (83.9 %) showed histological concordance and the remaining 46 (16.1 %) cases revealed an upgraded histology [22 high-grade dysplasia (7.7 %), and 24 differentiated adenocarcinoma (8.4 %)]. Univariate analyses demonstrated that lesion size, erythema, depression, and erosion were significant predictors of upgraded LGD ( $P < 0.001$ ). Multivariate analysis showed that a lesion size  $\geq 2$  cm, erythema, and a depressed-type lesion were independent predictors of upgraded histology ( $P = 0.014$ , odds ratio 3.27, 95 % confidence interval 1.28–8.39).

**Conclusions** Our data suggest that a substantial number of LGD diagnoses based on EFB were not representative of

the entire lesion. We recommend ER if gastric LGD has at least one of the following risk factors: surface erythema and a depressed type regardless of size, or  $\geq 2$  cm size regardless of abnormal surface configuration.

**Keywords** Biopsy · Endoscopic resection · Low-grade dysplasia · Size

## Introduction

Gastric cancer is the fourth most common cancer globally and the most commonly diagnosed cancer in Korea [1]. Since the Korean Government initiated the National Cancer Screening Program in 1999, gastric epithelial dysplasia is often identified in clinical practice, and is believed to be the penultimate stage of gastric carcinogenesis [2, 3]. However, no coincident international guidelines for the management of such lesions exist [4]. Previous studies suggested that most patients harboring biopsy-proven high-grade dysplasia (HGD) are at high risk of synchronous invasive carcinoma or it appears soon after a diagnosis with uniform endoscopic or surgical HGD resection [5, 6]. In comparison with HGD, patients with low-grade dysplasia (LGD) are less likely to progress to invasive carcinoma; however, data on the natural course of such patients are inconsistent [7–9]. Thus, endoscopic surveillance at regular intervals or endoscopic resection (ER) appears to be indicated, although the cost-effectiveness of this approach requires further evaluation [4].

Endoscopic forceps biopsies (EFB) are crucial for grading preneoplastic gastric lesions and determining an appropriate treatment strategy. Since EFB specimens are not representative of the entire lesion, significant histologic discrepancies have been found between diagnoses based on

M. K. Kim · J. Y. Jang (✉) · J.-W. Kim · J.-J. Shim ·  
C. K. Lee · Y. W. Chang  
Division of Gastroenterology, Department of Internal Medicine,  
College of Medicine, Kyung Hee University, Hoegi-dong 1,  
Dongdaemoon-gu, Seoul 130-702, South Korea  
e-mail: jyjang@khu.ac.kr

B. K. Choe  
Department of Preventive Medicine, College of Medicine,  
Kyung Hee University, Seoul, South Korea

EFB and subsequent ER. Recent reports indicate that 19 % of histological diagnosis of LGD in forceps biopsies may be upgraded to HGD, or even adenocarcinoma, after ER [10, 11]. Also, ER should be considered for accurate diagnosis and treatment when two of the following three risk factors are present: depressed morphology, surface erythema, or size  $\geq 1$  cm [10].

The size of LGD lesions influences the accuracy of EFB, and the accuracy of endoscopic ultrasonography (EUS) is associated with the size of early gastric cancer [12, 13]. Preoperative staging accuracy of gastric cancer by EUS decreases considerably from 83.3 to 58.3 % with increasing tumor size [13]. The concurrence rate of large lesion diagnosis is lower than that of smaller lesions [12]. Moreover, conventional white-light endoscopy cannot accurately differentiate and diagnose pre-neoplastic gastric conditions or lesions [4]. For this reason, precise target biopsies under conventional endoscopy are difficult for most clinicians. Imprecise EFB may be the main cause of such histological discrepancy. Thus, we hypothesized that measured lesion size may be a more reliable indicator of LGD than endoscopic features, such as surface erythema or depressed morphology. However, to our knowledge no studies have assessed lesion size as an indication for ER. The aim of this study was to determine whether lesion size is a risk factor for histological discrepancy, and propose a lesion size cut-off as a guideline for performance of ER.

## Materials and Methods

### Subjects

The study was conducted retrospectively in patients diagnosed with low-grade gastric dysplasia from endoscopic biopsy who had undergone ER from January 2007 to December 2010 at Kyung Hee University Hospital in Seoul, Korea. The numbers of initial diagnostic endoscopies performed were as follows: 121 patients (47 %) underwent procedures at outside clinics and 136 patients (53 %) at Kyung Hee University Hospital. Patients who underwent repeated ER at the same location were excluded. Based on tissue biopsy, 285 cases in 257 patients were diagnosed as LGD, and ER was performed in all. The influences of a history of smoking and alcohol consumption, defined as 10 g/day equivalent to two cups of Soju, were investigated and compared.

This study was approved by the Institutional Review Board of Kyung Hee University Hospital (KMC IRB 1216-05), and written informed consent for the endoscopic resection was obtained from all patients before the procedure.

### Upper Gastrointestinal Endoscopy and Endoscopic Findings

Upper gastrointestinal endoscopy (GIF-H260, Olympus Medical Systems Co., Ltd., Tokyo, Japan) and tissue biopsy (Olympus FB-24 K-1, Olympus Medical Systems Co., Ltd., Tokyo, Japan) were performed in all cases. The presence/absence of atrophic gastritis and intestinal metaplasia were noted during endoscopy procedures.

It is generally believed that gastric cancer development is a prolonged process that begins with atrophic gastritis, followed by intestinal metaplasia [14]. In our study, atrophic gastritis was identified upon observation of blood vessels on the gastric mucosa without excessive air-lining, and its severity was assessed using the Kimura–Takemoto classification [15]. Intestinal metaplasia was identified upon observation of white–grey-colored nodules on the gastric mucosa, and of tubal-shaped pits upon close examination. Tissue sections were collected from the gastric antrum and body and the Rapid Urease Test (CLO test, Delta West Pty Ltd., Bentley, Western Australia) was performed to verify the presence/absence of *Helicobacter pylori*.

Four endoscopy specialists analyzed the findings of all the study subjects using endoscopic photos at the time of initial diagnosis to evaluate the shape, color, size and location of lesions regardless of first endoscopic reports, and they were blinded to the results of the final histology. To rule out the subjective judgment of the investigator, the shape of the lesion was described simply as elevated, flat or depressed. When the lesion was depressed lower than the surrounding mucosa, regardless of its shape, it was defined as a depressed-type lesion. The elevated type was matched to type 0-I (protruding), type 0-IIa (superficial elevated), and 0-I + IIa of the Paris classification. The flat type corresponded to type IIb (flat) of the Paris classification, and the depressed type was matched to type 0-IIc (superficial shallow depressed), or type 0-III (excavated), 0-IIc + IIa, and 0-IIa + IIc [16]. The color of the lesion was described by comparing it to a discolored lesion that was whiter than the overall adjacent area, accompanied by surface erythema. The surface erythema standard was defined as a case accompanied with  $\geq 50$  % in lesion color tone. The presence/absence of erosion and ulcers was evaluated based on endoscopic pictures obtained from the referring private practice clinic to rule out tissue-biopsy-induced mucosal erosion and ulceration. The size of the lesion was compared with that measured after ER. Lesion location was determined by dividing it by the longitudinal axis and the transversal axis. For the longitudinal axis, measurements were performed after classification as an antral lesion, which comprised the pylorus and antral regions, and a body lesion, which comprised the angle

region, the body and the cardia. Disagreement in the analysis of the endoscopic photo between endoscopists was considered to be a median score. To investigate the ratio of histological discrepancy between the pathologic results after biopsy and after resection, the numbers of biopsies were determined. In referred patients, the number of biopsies was verified using the pathology report.

### Endoscopic Resection

ER was performed by an experienced endoscopist within 1 month from initial diagnosis. Information regarding pre-procedure methods and the potential complications was explained to patients and informed consent obtained. Endoscopic mucosal resection (EMR) and endoscopic submucosal dissection (ESD) were performed as part of the ER. EMR was performed for small lesions  $\pm 0.5$  cm, while ESD was performed in all cases with lesions  $\geq 1$  cm. EMR was performed as EMR-P (precutting), which resects the lesion using the snare after circumferential incision to avoid incomplete resection of the transverse section. During the procedure, the lesion was marked 5 mm outside the external margin using APC (argon plasma coagulation; ERBE, Tübingen, Germany), and locally injected with a mixed solution of glycerin, epinephrine and indigo carmine at this mark to lift the target. Incisions were made external to the lifted lesion using a needle knife (KD-V451 M, Olympus Medical Systems Co., Ltd., Tokyo, Japan) or IT knife2 (KD-611L, Olympus Medical Systems Co., Ltd., Tokyo, Japan). VIO 300D (ERBE, Tübingen, Germany) was used as the electrosurgical unit. In the EMR-P procedure, after a circumferential mucosal incision was performed, the snare (SD-210U-15, 25, Olympus Medical Systems Co., Ltd., Tokyo, Japan) was mounted along the incision groove and used to dissect the lesion. In the ESD procedure, an IT knife2 was placed into the incision site and the resection was completed by submucosal dissection parallel to the muscular layer. Regarding complications, bleeding was defined as procedure-related bleeding regardless of the time from the ER. We investigated the perforation including micro- and macro-perforation.

### Pathological Diagnosis

Pathological diagnosis of biopsy specimens was performed by three experienced pathologists and post-EMR and -ESD pathological diagnoses were conducted by a single pathologist. Tissue was cut into 2-mm sections after resection and slides prepared. Pathologic diagnosis was conducted in accordance with the Vienna classification and pathologic grading was divided into LGD, HGD, and well- and micro-differentiated adenocarcinoma [6, 17]. If pathologic findings showed a mixed lesion, we classified the lesion as the higher

grade, for example, when the lesion consisted of LGD with HGD, it was classified as HGD. We classified cases diagnosed as LGD from biopsy after resection of the LGD as the low-grade concordant group, while cases diagnosed as HGD or adenocarcinoma were classified as the low-grade upgraded group. The risk factors of these patients were determined.

### Statistical Analysis

SPSS version 18.0 (SPSS Inc., Chicago, Illinois, USA) was used for statistical analysis. Continuous variables are expressed as mean  $\pm$  standard deviation, and categorical variables as percentages. An independent *t* test was used for comparisons of the means of continuous variables, while differences in categorical variables were assessed using an  $\chi^2$  test. Risk factors in the upgraded groups were subjected to logistic regression analysis. Statistical significance was considered at  $P < 0.05$ .

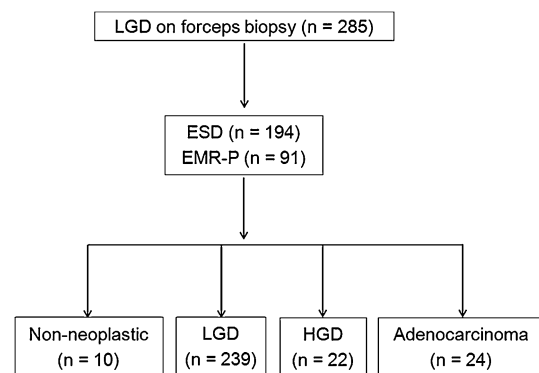
## Results

### Histological Discrepancy Between Biopsy- and Endoscopic-Resection Specimens

Of the 285 cases diagnosed as LGD by biopsy, 239 cases (83.9 %) were diagnosed as LGD after ER, 22 as HGD, and 24 cases as adenocarcinoma. Thus, the upgraded histological discrepancy rate was 16.1 % (Fig. 1; Table 1). Adenocarcinoma was differentiated in all cases, and in two of these cases, submucosal infiltration  $< 500$   $\mu\text{m}$  was identified.

### Comparison of Clinical Factors Between the Low- and High-Grade Dysplasia Groups

No significant differences between the low-grade concordant and low-grade upgraded groups were identified in



**Fig. 1** Flow chart of diagnosis of gastric dysplastic lesions by forceps biopsy. *EMR-P* endoscopic mucosal resection with precutting, *ESD* endoscopic submucosal dissection, *HGD* high-grade dysplasia, *LGD* low-grade dysplasia

**Table 1** Baseline characteristics and endoscopic features of concordant and upgraded lesions after endoscopic resection

Characteristic	Low-grade dysplasia ( <i>n</i> = 285)		
	Concordant ( <i>n</i> = 239)	Upgraded ( <i>n</i> = 46)	<i>P</i> value
Age, years, mean ± SD	63.1 ± 8.8	67.6 ± 8.5	0.913
Male gender, <i>n</i> (%)	167 (70.2)	34 (73.9)	0.609
Smoking, <i>n</i> (%)	62 (26.1)	9 (19.6)	0.609
Alcohol, <i>n</i> (%)	117 (49.2)	23 (50.0)	0.917
<i>H. pylori</i> positivity, <i>n</i> (%)	125 (52.5)	21 (45.7)	0.785
Atrophic gastritis, <i>n</i> (%)	235 (98.7)	46 (100)	0.824
Intestinal metaplasia, <i>n</i> (%)	208 (87.4)	39 (84.8)	0.579
Number of biopsy fragments (mean ± SD)	2.0 ± 0.9	2.3 ± 1.0	0.158
Tumor location, longitudinal, <i>n</i> (%)			0.142
Antrum	125 (52.1)	31 (67.4)	
Body	110 (46.2)	14 (30.4)	
Cardia	4 (1.7)	1 (2.2)	
Tumor location, horizontal, <i>n</i> (%)			0.125
Anterior wall	40 (16.4)	14 (30.4)	
Greater curvature	38 (16.0)	4 (8.7)	
Posterior wall	61 (25.6)	11 (23.9)	
Lesser curvature	100 (42.0)	17 (41.2)	
Lesion size (mm, mean ± SD)	1.2 ± 0.9	2.0 ± 1.8	<0.001
Lesion size (long diameter), <i>n</i> (%)			0.006
<0.5 (cm)	26 (10.5)	4 (8.7)	
0.5–0.9 (cm)	79 (33.2)	9 (19.6)	
1.0–1.9 (cm)	102 (42.9)	16 (34.8)	
2.0–2.9 (cm)	20 (8.4)	10 (21.7)	
≥3.0 (cm)	12 (5.0)	7 (15.2)	
Surface configuration, <i>n</i> (%)			
Erythema	15 (6.3)	17 (37.0)	<0.001
Nodularity	24 (10.1)	5 (10.9)	0.872
Depression	4 (1.7)	7 (15.2)	<0.001
Erosion	17 (7.1)	12 (26.0)	<0.001

terms of age ( $63.1 \pm 8.8$  vs.  $67.6 \pm 8.5$ ,  $P = 0.913$ ), gender (males, 70.2 vs. 73.9 %,  $P = 0.609$ ), smoking (26.1 vs. 19.6 %,  $P = 0.609$ ), or history of alcohol consumption (49.2 vs. 50.0 %,  $P = 0.917$ , Table 1). Males comprised a higher proportion of both groups than females.

#### Comparison of Endoscopic Factors Between the Low- and High-Grade Dysplasia Groups

No significant difference in the rates of *H. pylori* (52.5 vs. 45.7 %,  $P = 0.785$ ), atrophic gastritis (98.7 vs. 100 %,  $P = 0.824$ ) and intestinal metaplasia (87.4 vs. 84.8 %,  $P = 0.579$ ) were found between the low-grade concordant and low-grade upgraded groups. Atrophic gastritis and intestinal metaplasia were observed in most cases in all groups. No significant differences in the number of biopsy samples and the longitudinal and transverse locations of the lesion were found between the low-grade concordant and

low-grade upgraded groups (Table 1). The lesions on the longitudinal side occurred primarily from the antral region, while those on the transverse side occurred mainly from the lesser curvature region.

The average size of lesions was significantly increased in the low-grade upgraded group ( $2.0 \pm 1.8$  cm) compared to the low-grade concordant group ( $1.2 \pm 0.9$  cm,  $P < 0.001$ ). The endoscopic characteristics of lesions in the low-grade upgraded group differed significantly in the numbers of surface erythema (6.3 vs. 37.0 %,  $P < 0.001$ ) and the rates of depressed type lesions (1.7 vs. 15.2 %,  $P < 0.001$ ) and erosion (7.1 vs. 26.0 %,  $P < 0.001$ ) in comparison to lesions in the low-grade concordant group (Table 1). Univariate analyses identified lesion size, surface erythema, a depressed type and erosion as significant predictors of a histological discrepancy compared to LGD in terms of the presence of an HGD abnormality in the lesion.

### Multivariate Analysis Based on Lesion Size in the Low-Grade Upgraded Group

When multivariate analysis was performed in the low-grade upgraded group, lesion size, surface erythema, depressed-type and erosion were identified as significant predictors. Lesions in the low-grade upgraded group were classified into five groups by size: <0.5, 0.5–0.9, 1.0–1.9, 2.0–2.9, and  $\geq 3.0$  cm. The number of biopsy samples, surface erythema frequencies and depressed-types were assessed (Table 2). The number of biopsy samples significantly increased with lesion size ( $P < 0.001$ ), but surface erythema and depressed-type lesions were distributed evenly regardless of size. Logistic analysis of lesion size, surface erythema and depressed-type identified these as risk factors for malignancy and an upgraded histological discrepancy, regardless of lesion size. A lesion  $\geq 2$  cm was an independent risk factor for malignancy, independently of depressed-type or surface erythema ( $P = 0.014$ , odds ratio [OR] 3.27, 95 % confidence interval [CI] 1.28–8.39, Table 3).

### Complications of Endoscopic Resection

Procedure-related bleeding occurred in six patients (2.3 %). These six patients were successfully managed under endoscopic technic. Perforation occurred in three patients (1.1 %) and they all recovered completely following medical treatment.

### Discussion

The present study assessed the rate of histologic discrepancies between EFB and ER specimens in patients with LGD. Lesion size was an independent risk factor for upgraded diagnosis and a reliable indication of ER.

With the rise in the number of endoscopies performed, driven in large part by individual screening, the detection of LGD has increased [18]. However, no international guidelines for the management of LGD are available [4]. Some researchers have suggested endoscopic surveillance at regular intervals with re-biopsy, while others have proposed ER

**Table 3** Logistic regression analysis of risk factors in upgraded low-grade dysplastic lesions

Risk factor	P value	Odds ratio	95 % CI	
			Lower	Upper
Size $\geq 0.5$ cm	0.62	0.85	0.36	3.70
Erythema	<0.001	7.94	3.32	19.01
Depression	0.003	8.57	2.07	35.4
Size $\geq 1.0$ cm	0.51	2.06	0.99	4.27
Erythema	<0.001	15.51	4.76	50.5
Depression	0.042	5.55	1.06	28.92
Size $\geq 2.0$ cm	0.014	3.27	1.28	8.39
Erythema	<0.001	5.26	2.1	13.16
Depression	0.01	6.72	1.59	28.46
Size $\geq 3.0$ cm	0.23	2.38	0.58	9.83
Erythema	<0.001	7.51	3.12	18.06
Depression	0.004	7.6	1.92	30.09

CI confidence interval

for accurate diagnosis and treatment of LGD. These disagreements may arise from differences in diagnostic criteria, the natural course of LGD, histologic discrepancy, sampling errors, and selection bias.

The primary cause of the variation in the natural course of LGD in previous studies is differences in diagnostic criteria, including grading and classification. For example, noninvasive intramucosal neoplastic lesions with high-grade cellular and architectural atypia are termed intramucosal carcinoma in Japan, whereas the same lesions are diagnosed as HGD by most pathologists in Western countries [19]. The Vienna classification for gastric dysplasia was developed as a consensus between Western and Asian countries [6, 17]. Yamada et al. [20] reported gastric adenoma follow-up data based on the Vienna classification, which demonstrated no cancer progression in patients with LGD. However, half of the patients in that study had lesions <0.5 cm, and most lesions were <1 cm. Thus, a majority of patients were excluded since they underwent ER or surgery due to a larger lesion or greater malignant potential. This selection bias may influence the prognosis of LGD, as stated by Cho et al. [10].

**Table 2** Distribution of endoscopic variables in upgraded low-grade dysplastic lesions

Variable	Size (cm)					P value
	<0.5	0.5–0.9	1.0–1.9	2.0–2.9	$\geq 3.0$	
Upgraded ( $N = 46$ ), $n$ (%)	4 (8.7)	9 (19.6)	16 (34.8)	10 (21.7)	7 (15.2)	0.006
Number of biopsies, mean $\pm$ SD	1.7 $\pm$ 0.7	1.7 $\pm$ 1.2	2.1 $\pm$ 0.8	2.6 $\pm$ 0.8	2.9 $\pm$ 1.3	<0.001
Erythema ( $N = 17$ ), $n$ (%)	0 (0)	3 (17.6)	4 (23.5)	4 (23.5)	6 (35.3)	<0.001
Depression ( $N = 7$ ), $n$ (%)	1 (0)	1 (14.3)	3 (42.9)	1 (14.3)	1 (14.3)	0.008

Even though EFB is the most accurate method of diagnosis of gastric mucosal lesions, it often yields inadequate tissue for histological diagnosis [21–24]. Conventional white-light endoscopy cannot accurately differentiate and diagnose pre-neoplastic gastric conditions [4]. Park et al. [9] reported that grading of gastric dysplastic lesions found in EFB from adenomas is not useful, since biopsy-proven LGD does not exclude the presence of HGD or cancer foci in another part of the gastric adenoma. As a result, histologic discrepancy has been reported in 19 % of lesions studied in Korea, in which LGD detected in a forceps biopsy may be upgraded to a diagnosis of HGD, or even adenocarcinoma [11]. The LGD histological discrepancy rate between EFB and ER specimens was 16.1 % in our study. Our results were in accordance with the previous reports.

The lesion size of patients with LGD is an important factor affecting the accuracy of EFB. Larger gastric LGD have a higher rate of histologic discrepancies between EFB and ER. Lee et al. [12] reported that the concurrence of diagnosis prior to and after ER was 39 % for lesions >2 cm and 62 % for those <2 cm. Moreover, the malignant transformation rate of adenomas increased with increasing lesion size [9]. Adenomas >2 cm in diameter are regarded as having malignant potential. Multivariate logistic regression analysis indicated that in lesions <2 cm, the OR was high, irrespective of endoscopic characteristics, depression or surface erythema. A strength of our study is that the lesion size ( $\geq 2$  cm) was an independent risk factor for lesions with LGD having HGD or cancer foci (OR 3.27, 95 % CI 1.28–8.39). In addition to lesion size, we also found that surface erythema and depressed morphology were independent risk factors for upgraded diagnosis after ER, regardless of lesion size, which differs from previous reports. Also, we analyzed endoscopic risk factors according to the number of biopsy samples and showed that it increased with lesion size. Therefore, this means that a lower number of biopsy samples did not contribute to histologic discrepancy in the large lesions.

Although technical developments, such as magnifying endoscopy and narrow-band imaging (NBI), have improved the diagnostic accuracy for gastric LGD, the discrepancy between diagnosis by EFB and by ER continues to be a concern [25]. These new techniques are superior to ordinary white-light endoscopy in terms of differential diagnosis of small cancerous or non-cancerous lesions [26]. However, the rate of larger lesions missed by NBI and conventional imaging is similar, and not all centers are equipped similarly [27]. Repeated and numerous biopsies may enable correct diagnosis. Accurate acquisition of biopsy specimens comprising at least three to four pieces from the region in which the mucosal change is observed is important, but there is no international

agreement regarding how many specimens or biopsies are sufficient [28]. In addition, endoscopists tend to perform passive biopsies when considering ER for fibrosis, which is thought to increase the histological discrepancy rate even though the number of biopsies taken tends to increase according to lesion size.

In routine practice, clinicians could not judge a definitive dysplastic grade of the lesion during endoscopy. Moreover, aggressive biopsy might leave a fibrosis. Therefore, determining adequate number of biopsies can be a truly difficult task. In this way, we thought adequate biopsy location and technique were more important than large number of biopsies. With regards biopsy location, performing a target biopsy on more depressed and erythematous portions of a lesion might be able to show higher yield for an adequate histological diagnosis. If the lesion size was too large to identify the surface characteristics, ER should be considered for accurate diagnosis. Technically, the turn-and-suction biopsy technique is preferred over the push-off or lift-and-cut techniques because it permits the acquisition of larger mucosal samples [29]. Put simply, first the biopsy forceps is advanced into the opened lumen, and withdrawn backward until it is flush with the endoscope tip. Next, the endoscope tip is turned gently into the wall while air is suctioned from the lumen, and the biopsy forceps is very slightly advanced and then closed, usually without direct visualization [29].

The purpose of ER is accurate diagnosis and complete removal of diseased mucosa. Indeed, ER as diagnosis for LGD is more invasive than forceps biopsies and carries a risk of complications including perforation, bleeding and hospital admission, in addition to the increased medical expenses. However, mucosal ER of early gastric cancer is a standard technique in Korea and Japan, since it is less invasive and more physiological than conventional surgery. ER is more favorable and reliable than EFB for *en bloc* resection of the entire lesion, and may provide a sample representative of the entire lesion.

Similar studies identified the endoscopic risk factors for histologic discrepancy in patients with LGD. According to Cho et al. [10] if a LGD has two or more risk factors, including depressed morphology, surface erythema, and a size of  $\geq 1$  cm, ER is recommended for diagnostic and therapeutic purposes. Kim et al. [11] assessed ER for gastric LGD measuring  $\geq 2$  cm and concluded that lesions that did not display a whitish discoloration should be considered.

The concern about appropriateness of ER for patients with LGD still exists at present, because LGD is not an indication for ER according to the Vienna classification. Although the risk of progression from LGD to invasive gastric cancer is low (approximately 3–9 %), it can progress during follow up [8, 30]. In a recent study performed in

Korea, a total of seven (26.9 %) out of 26 patients with LGD revealed progressive dysplasia regardless of size during follow-up examinations, even though there was a small number of cases with a lack of statistical power [31]. Also, fatal complications of ER were extremely low and medical costs were relatively inexpensive compared with those of the United States. Therefore, considering high histologic discrepancy rate of LGD (16–20 %), high prevalence rate of gastric cancer and other factors as stated above, ER of LGD was thought to be a reasonable decision in Korea, and several studies from Korea about gastric adenoma have included small size LGD [11, 32]. However, this treatment strategy in Korea may change if the evidence about low potential risk of small LGD is enough in the near future.

This study has some limitations. The first is that, as a retrospective study, the results are less reliable than those of a prospective study. However, this limitation can be overcome by the statistical power of the much larger sample size included in the study. Second, no case of low-grade dysplasia was observed over its natural course without treatment; hence, we could not analyze the risk factors for malignant transformation. Third, all ER specimens were interpreted by a single pathologist, and inter-observer variability may have caused all the lesions to be completely removed by the ER, ensuring reliable pathological diagnosis. In addition, pathologists were not blinded to the findings of the previous biopsies or the clinical suspicion of the endoscopist. Lastly, we did not include subjects who were unable to perform ER due to poor patient condition such as extremely old age or severe concomitant disease. Therefore, this result was not completely free of possible selection bias.

In conclusion, EFB does not provide a sample representative of the entire lesion for definitive diagnosis and accurate management of patients with LGD. Additionally, the rate of upgraded diagnosis in biopsy-proven LGD before and after ER is high if risk factors, such as large size, surface erythema or depressed morphology, are present in the lesion. Therefore, we propose that ER should be considered if the LGD has surface erythema or depression, regardless of size, or when the lesion is larger than 2 cm, regardless of the endoscopic findings.

**Conflict of interest** None.

## References

- Shin HR, Won YJ, Jung KW, et al. Nationwide cancer incidence in Korea, 1999–2001; first result using the national cancer incidence database. *Cancer Res Treat*. 2005;37:325–331.
- Ming SC, Bajtai A, Correa P, et al. Gastric dysplasia. Significance and pathologic criteria. *Cancer*. 1984;54:1794–1801.
- Morson BC, Sobin LH, Grundmann E, Johansen A, Nagayo T, Serck-Hanssen A. Precancerous conditions and epithelial dysplasia in the stomach. *J Clin Pathol*. 1980;33:711–721.
- Dinis-Ribeiro M, Areia M, de Vries AC, et al. Management of precancerous conditions and lesions in the stomach (MAPS): guideline from the European Society of Gastrointestinal Endoscopy (ESGE), European Helicobacter Study Group (EHSO), European Society of Pathology (ESP), and the Sociedade Portuguesa de Endoscopia Digestiva (SPED). *Endoscopy*. 2012;44:74–94.
- Jeon SW. Endoscopic management of gastric dysplasia: cutting edge technology needs a new paradigm. *World J Gastrointest Endosc*. 2010;2:301–304.
- Dixon MF. Gastrointestinal epithelial neoplasia: Vienna revisited. *Gut*. 2002;51:130–131.
- Di Gregorio C, Morandi P, Fante R, De Gaetani C. Gastric dysplasia. A follow-up study. *Am J Gastroenterol*. 1993;88:1714–1719.
- Rugge M, Farinati F, Baffa R, et al. Gastric epithelial dysplasia in the natural history of gastric cancer: a multicenter prospective follow-up study. Interdisciplinary Group on Gastric Epithelial Dysplasia. *Gastroenterology*. 1994;107:1288–1296.
- Park DI, Rhee PL, Kim JE, et al. Risk factors suggesting malignant transformation of gastric adenoma: univariate and multivariate analysis. *Endoscopy*. 2001;33:501–506.
- Cho SJ, Choi IJ, Kim CG, et al. Risk of high-grade dysplasia or carcinoma in gastric biopsy-proven low-grade dysplasia: an analysis using the Vienna classification. *Endoscopy*. 2011;43:465–471.
- Kim YJ, Park JC, Kim JH, et al. Histologic diagnosis based on forceps biopsy is not adequate for determining endoscopic treatment of gastric adenomatous lesions. *Endoscopy*. 2010;42:620–626.
- Lee SB, Kang HY, Kim KI, Ahn DH. The diagnostic accuracy of endoscopic biopsy for gastric dysplasia. *J Gastric Cancer*. 2010;10:175–181.
- Kim JH, Song KS, Youn YH, et al. Clinicopathologic factors influence accurate endosonographic assessment for early gastric cancer. *Gastrointest Endosc*. 2007;66:901–908.
- Correa P, Houghton J. Carcinogenesis of *Helicobacter pylori*. *Gastroenterology*. 2007;133:659–672.
- Kimura K, Takemoto T. An endoscopic recognition of the atrophic border and its significance in chronic gastritis. *Endoscopy*. 1969;1:87–96.
- Endoscopic Classification Review Group. Update on the Paris classification of superficial neoplastic lesions in the digestive tract. *Endoscopy*. 2005;37:570–578.
- Schlemper RJ, Riddell RH, Kato Y, et al. The Vienna classification of gastrointestinal epithelial neoplasia. *Gut*. 2000;47:251–255.
- Yeh JM, Hur C, Kuntz KM, Ezzati M, Goldie SJ. Cost-effectiveness of treatment and endoscopic surveillance of precancerous lesions to prevent gastric cancer. *Cancer*. 2010;116:2941–2953.
- Lauwers GY, Srivastava A. Gastric preneoplastic lesions and epithelial dysplasia. *Gastroenterol Clin North Am*. 2007;36:813–829, vi.
- Yamada H, Ikegami M, Shimoda T, Takagi N, Maruyama M. Long-term follow-up study of gastric adenoma/dysplasia. *Endoscopy*. 2004;36:390–396.
- Gowen GF. Endoscopic biopsy for improved accuracy in upper gastrointestinal tract diagnosis. *Arch Surg*. 1982;117:485–489.
- Remmele W, Kolb EF. Malignant transformation of hyperplastic polyps of the stomach—case report. *Endoscopy*. 1978;10:63–65.
- Ginsberg GG, Al-Kawas FH, Fleischer DE, Reilly HF, Benjamin SB. Gastric polyps: relationship of size and histology to cancer risk. *Am J Gastroenterol*. 1996;91:714–717.
- Muehldorfer SM, Stolte M, Martus P, Hahn EG, Ell C. Multi-center Study Group “Gastric Polyps”. Diagnostic accuracy of forceps biopsy versus polypectomy for gastric polyps: a prospective multicentre study. *Gut*. 2002;50:465–470.

25. Mine T. The role of magnifying endoscopy in the diagnosis of early gastric carcinoma. *J Gastroenterol*. 2006;41:397–398.
26. Hirata I, Nakagawa Y, Ohkubo M, Yahagi N, Yao K. Usefulness of magnifying narrow-band imaging endoscopy for the diagnosis of gastric and colorectal lesions. *Digestion*. 2012;85:74–79.
27. Sabbagh LC, Reveiz L, Aponte D, de Aguiar S. Narrow-band imaging does not improve detection of colorectal polyps when compared to conventional colonoscopy: a randomized controlled trial and meta-analysis of published studies. *BMC Gastroenterol*. 2011;11:100–112.
28. Haber MM. Gastric biopsies: increasing the yield. *Clin Gastroenterol Hepatol*. 2007;5:160–165.
29. Levine DS, Reid BJ. Endoscopic biopsy technique for acquiring larger mucosal samples. *Gastrointest Endosc*. 1991;37:332–337.
30. Rugge M, Cassaro M, Di Mario F, et al. The long term outcome of gastric non-invasive neoplasia. *Gut*. 2003;52:1111–1116.
31. Park SY, Jeon SW, Jung MK, et al. Long-term follow-up study of gastric intraepithelial neoplasias: progression from low-grade dysplasia to invasive carcinoma. *Eur J Gastroenterol Hepatol*. 2008;20:966–970.
32. Kim SY, Sung SK, Moon HS, et al. Is endoscopic mucosal resection a sufficient treatment for low-grade gastric epithelial dysplasia? *Gut Liver*. 2012;6:446–451.