Management of incidentally found gastric adenoma/dysplasia

Jun Haeng Lee. Department of Medicine
Sungkyunkwanuniversity School of Medicie, Seoul, Korea

Similar limitations between Barrett's dysplasia and gastric adenoma/dysplasia

- Ideally, the management of a disorder is based on
  - an unequivocal diagnosis,
  - a firm understanding of the natural history, and
  - definitive data regarding the risks and benefits of the treatment options.
- Unfortunately, none of these prerequisite factors may be available to guide the management of patients with dysplasia in Barrett's esophagus.

Spechler SJ. Am J Gastroenterol 2005;100:927-935

Do we have unequivocal diagnosis?

Jun Haeng Lee. Department of Medicine
Sungkyunkwanuniversity School of Medicie, Seoul, Korea

Problem 1: What is dysplasia?

- Abnormality of development; in pathology, alteration in size, shape, and organization of adult cells *(Dorlands' dictionary 24th ed.)*
- Unequivocal **neoplastic transformation** of the epithelium *(Riddell RH. Hum Pathol 1983)*
- Histological expression of genetic alterations that favor cell growth and neoplasia *(Spechler. Gastroenterology 2001)*
- In Japan, some authorities defined biopsies with marked reactive and regenerative histological features as dyplasia *(Goldstein NS. Hum Pathol 1997)*

What is adenoma?

- Adenoma = dysplasia

위선종은 WHO의 종양 분류에 따르면 intraepithelial neoplasia-adenoma다. 일본에서는 융기형, 평탄형, 함몰형을 모두 선종이라 한다. 서양에서는 경계가 분명한 융기형을 선종이라 하고 나머지 모두를 epithelial dysplasia라고 한다. Histology는 tubular, tubulovillous, villous로 나눈다. Grade는 low grade dysplasia와 high grade dysplasia로 나누며, 핵의 길이가 세포 길이의 1/2 이하인 경우 low grade dysplasia로 분류하고, 인접한 세 개 이상의 선구조가 high grade dysplasia (핵의 길이가 세포 길이의 1/2 이상)의 소견을 보일 경우 high grade dysplasia로 분류한다.

- In western countries, well demarcated elevated lesions are called as adenomas, and others as dysplasias.
- In eastern countries, not only elevated, but also flat/depressed lesions are called as adenomas.

소화기병리학연구회. 위암 병리보고서 기재사항 표준화. 대한병리학회지 2005;39:106

Adenomas with LGD – elevated type

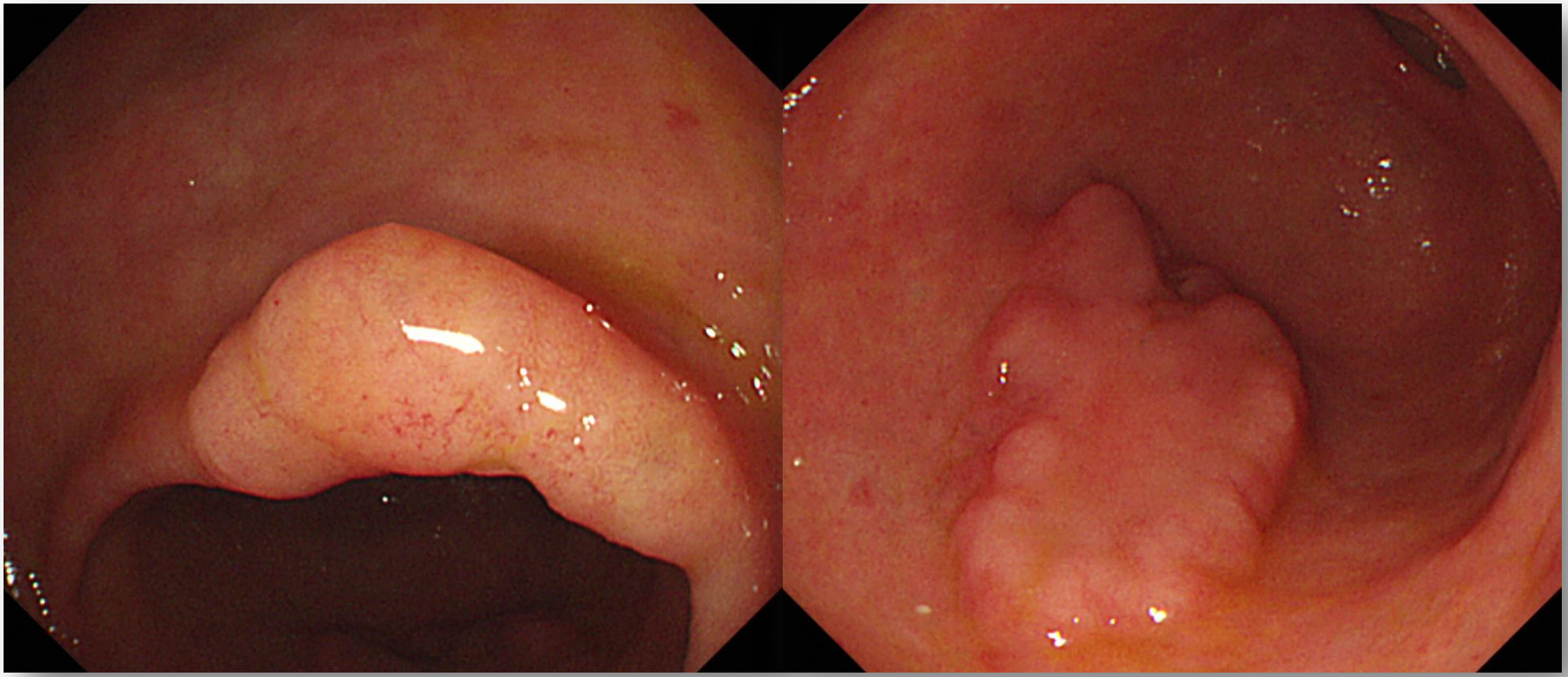

Adenoma with HGD – flat type

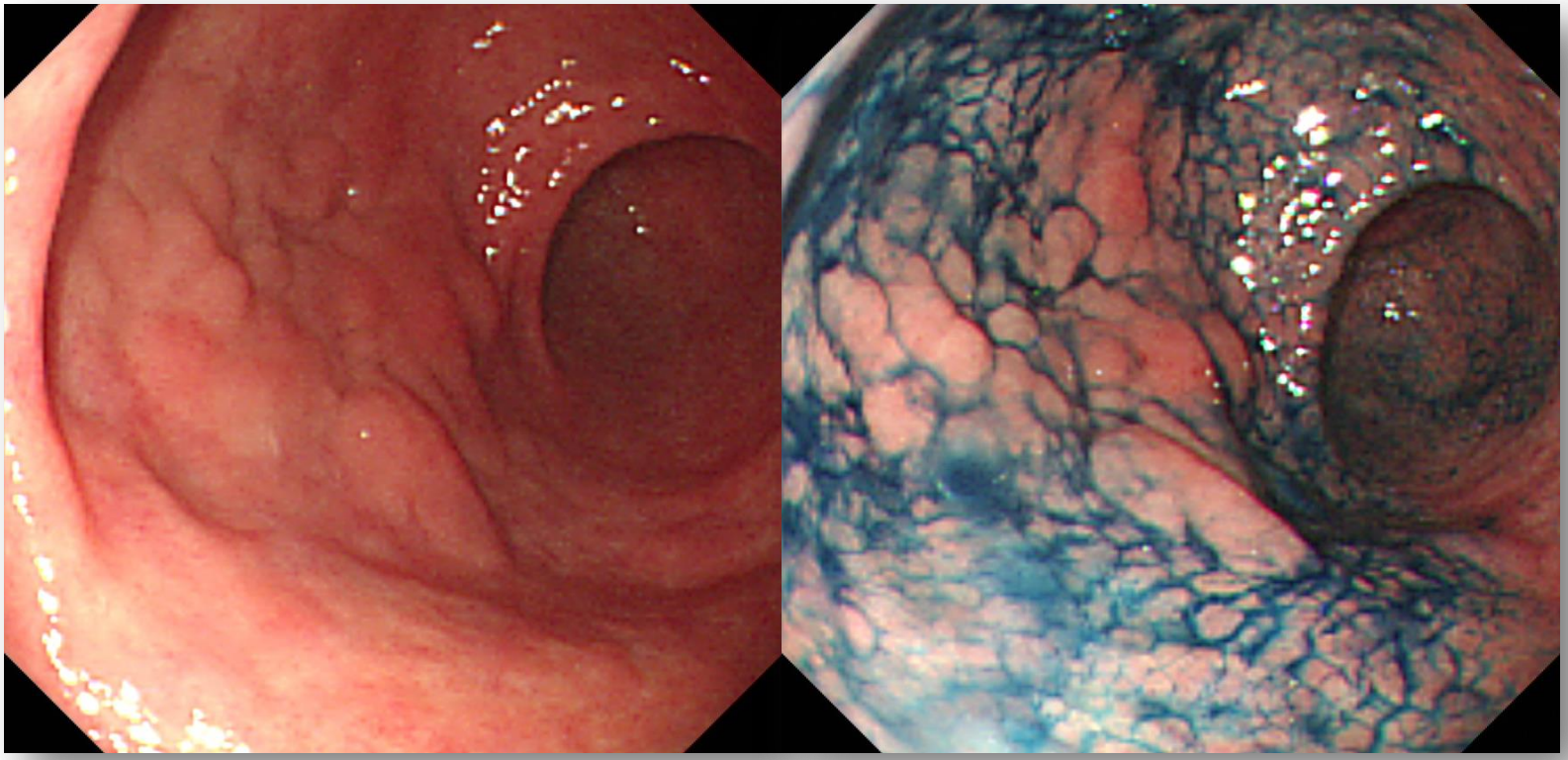

Adenoma with HGD – depressed type

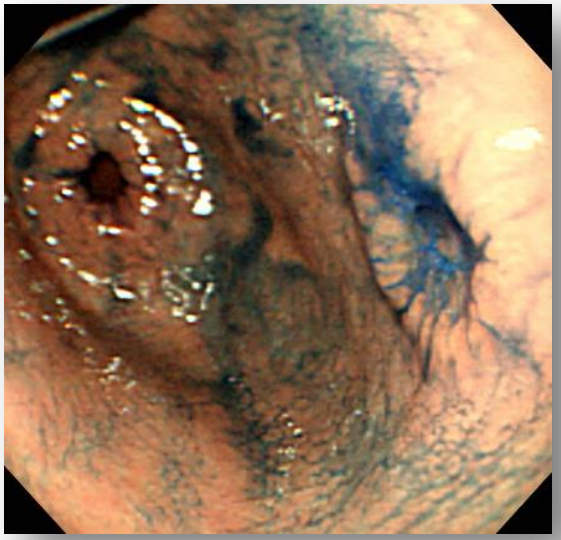

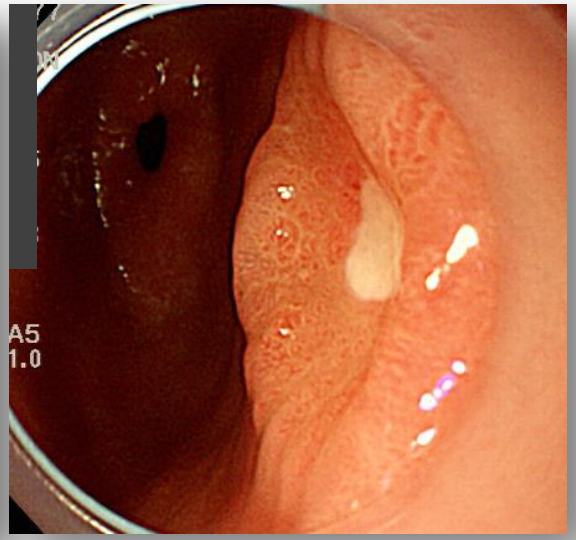

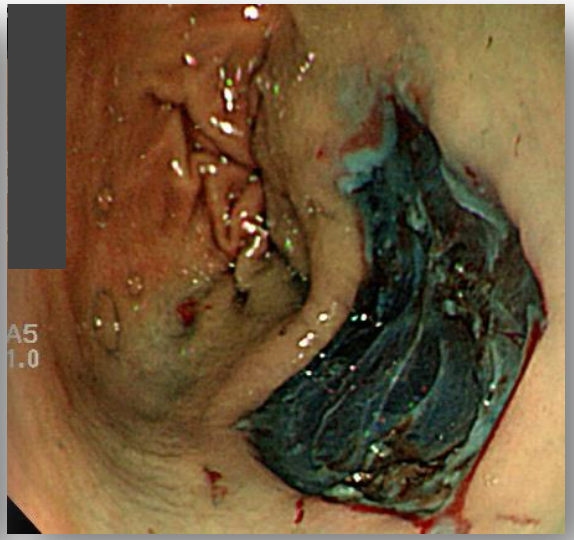

Regenerating atypia *vs.* dysplasia

- Changes in epithelial cells (e.g. increased N/C ratio +/- structural disarray) may occur in two situations.
- **Regenerating atypia** - when the eithelium has been injured and is undergoing repair
- **Dysplasia** - when genetic alterations have transformed the cells in a neoplastic growth
- Significant overlap exist between the two.

Conceptual model

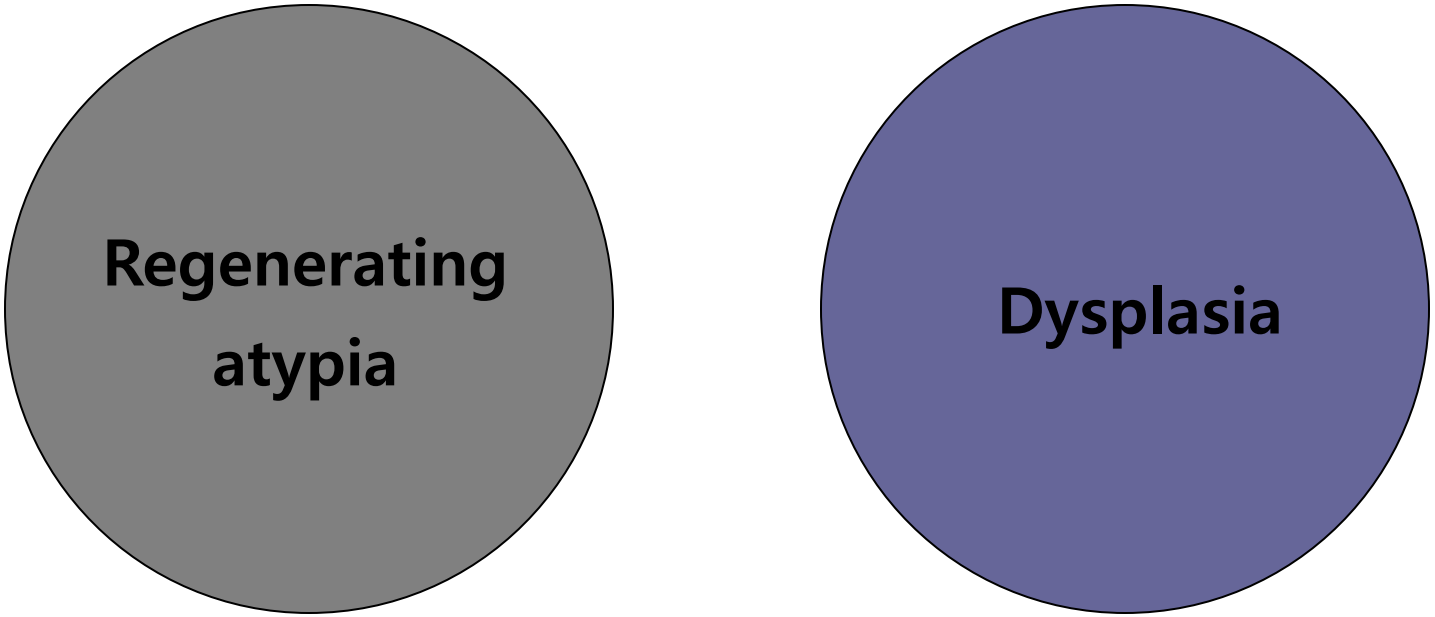

In clinical practice

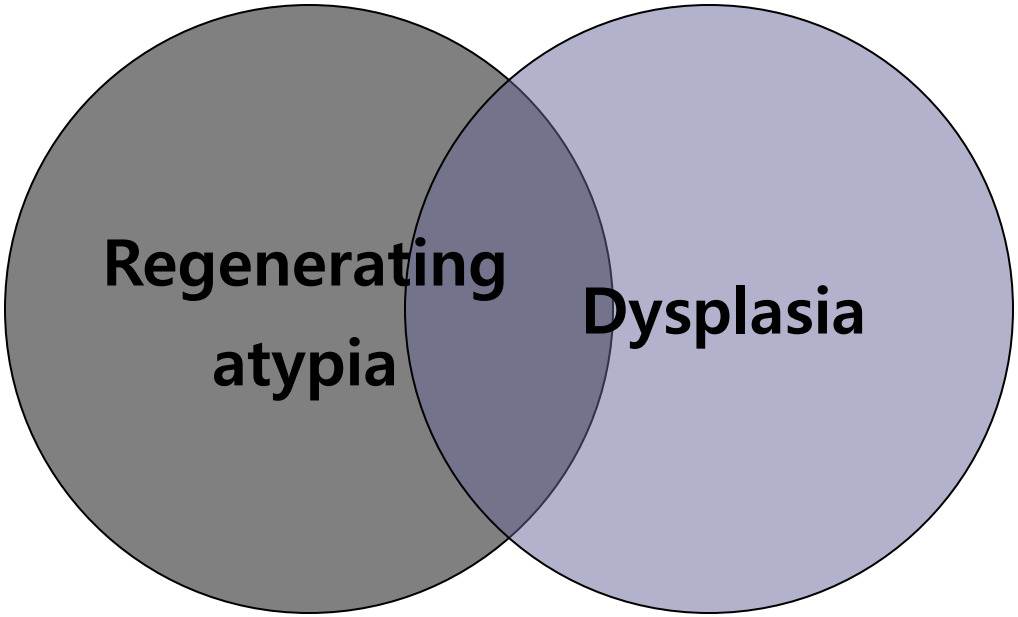

Biopsy: adenoma with LGD

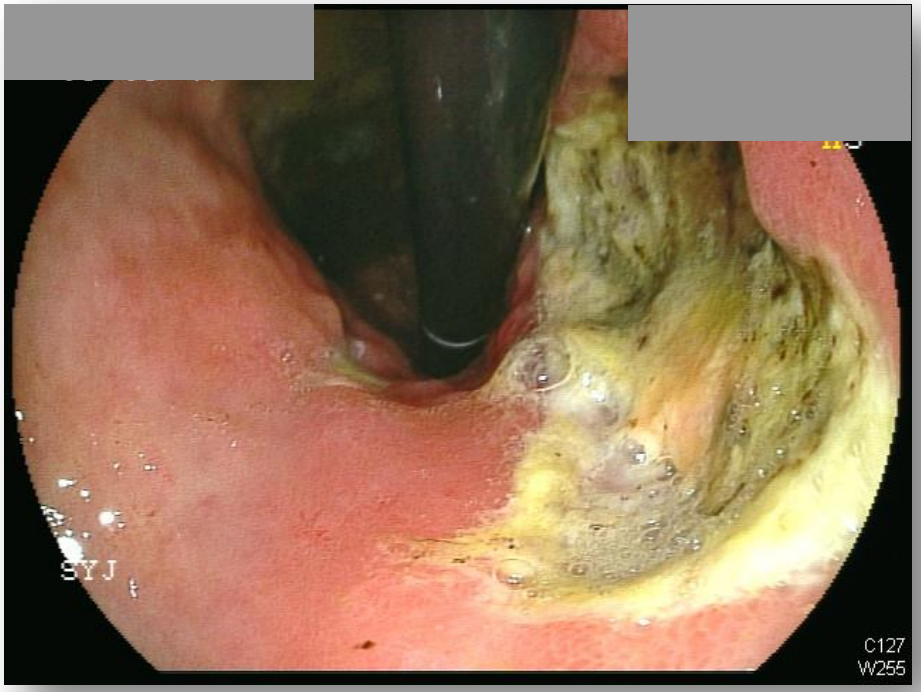

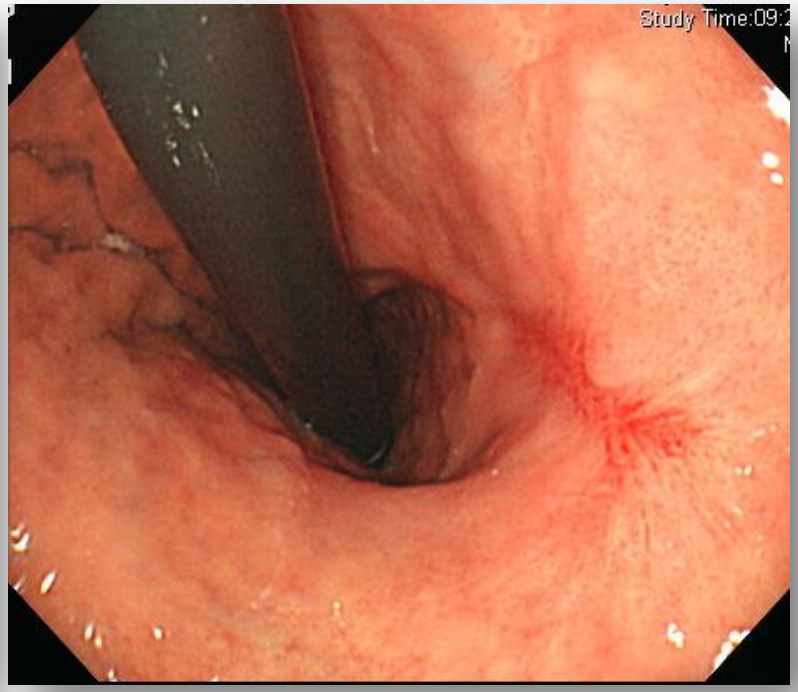

Problem 2: Inter-national variation in pathological evaluation of dysplasias

Author, year and reference	Dysplasia and related lesions (from Goldstein and Lewin, 1997, modified) [7]				
Takagi *et al.* 1967 [11]	Benign	Borderline	Carcinoma		
Nagayo 1971 [12]	Atypical	Borderline lesion	Probable cancer	Definitive cancer	
Grundmann 1975 [1]	Low-grade GED	High-grade GED	Invasive cancer		
Oehlert *et al.* 1975 [2]	Slight GED	Moderate GED	Severe GED	Invasive cancer	
Morson *et al.* 1980 [3]	Regenerative	Mild GED	Moderate GED	Severe GED	Invasive cancer
Ming *et al.* 1984 [5]	Grade 1 GED	Grade 2 GED	Grade 3 GED	Grade 4 GED	Invasive cancer
Japanese classification of gastric carcinoma 1995 [13]	Group I lesions	Group II lesions	Group III–IV lesions	Group V lesions	
Goldstein and Lewin 1997 [7] (as proposed by Riddell 1983)	Reactive	Indefinite for GED	Low-grade GED	High-grade GED	Invasive cancer

GED, gastric epithelial dysplasia.

Rugge. Eur J Gastroenterol Hepatol 2005;17:1191-1196

Group classification of JRSGC since 1971

Group	Diagnosis
Group I	Normal mucosa and benign lesions with no atypia
Group II	Lesions showing atypiaa but are diagnosed as benign (non-neoplastic)
Group III	Borderline lesions between benign (non-neoplastic) and malignant
Group IV	Lesions strongly suspected of carcinoma
Group V	Carcinoma

Nagano T. Gann Monogr Cancer Res 1971;11:245-256

Kato. Stomach & Intestine 2004;39:1443-1447

Japanese	Western	Vienna, 1998
1. normal and benign lesion with no atypia	negative for dysplasia	1. negative for neoplasia/dysplasia
2. benign non-neoplastic lesion		
3. borderline lesion	indefinite for dysplasia	2. indefinite
	low grade adenoma/dysplasia	3. noninvasive low-grade neoplasia
	high grade adenoma/dysplasia	4.1 high-grade adenoma/dysplasia
4. lesions strongly suspected of carcinoma		
5. carcinoma		4.2 carcinoma in situ
	suspicious for invasive carcinoma	4.3 suspicion of invasive carcinoma
	invasive carcinoma	5. invasive carcinoma

Schlemper. Gut 2000;47:251-255

Western vs. Japanese view

- pathologic diagnosis of 35 cases

Table 1. Distribution of diagnoses by individual pathologists

	Western viewpoint				Japanese viewpoint					
Diagnosis	K.L.	R.R.	P.S.	Total	M.S.	M.I.	Y.K.	T.S.	H.W.	Total
Reactive epithelium	2	3	1*	6 (6%)	1	2	3	3	2	11 (6%)
LGD/adenoma†	3	8	9	20 (19%)	1	1	1	1	1	5 (3%)
HGD/adenoma‡	14	8	17	39 (37%)	1	1	2	2	1	7 (4%)
Suspected CA	7	7	5	19 (18%)	0	4	5	3	0	12 (7%)
Definite CA	9	9	3	21 (20%)	32	27	24	26	31	140 (80%)
Total	35	35	35	105 (100%)	35	35	35	35	35	175 (100%)

CA, Carcinoma.
*Including indefinite for dysplasia.
†*LGD*, Low-grade dysplasia, used in the West; adenoma with slight or moderate atypia, used in Japan.
‡*HGD*, High-grade dysplasia, used in the West; adenoma with severe atypia used in Japan.
Reprinted with permission from Elsevier Science (The Lancet 1997;349:1725).

Schlemper RJ. Lancet 1997;349:1725-1729

Willis & Riddell. Gastrointest Endosc 2003;57:369-376

Gastric adenoma with HGD in Korea may be gastric cancer in Japan.

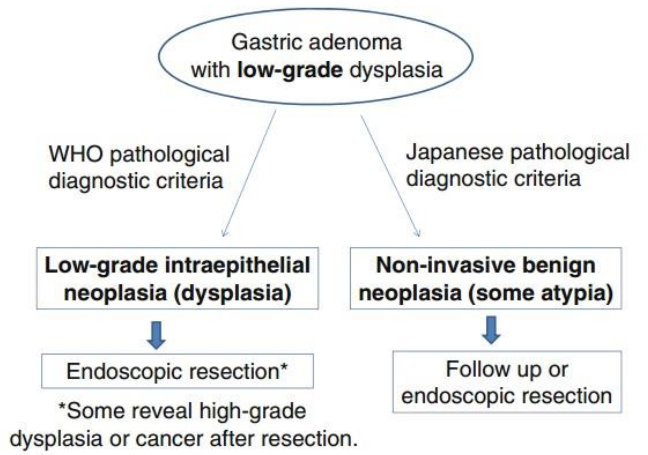

Fig. 2 Different diagnosis and management for gastric adenoma with low-grade dysplasia. According to the Japanese classification of gastric carcinoma, low-grade dysplasia is closer to group 3 (benign neoplasia) and some of group 2 (atypical epithelium which cannot be diagnosed as neoplastic atypia) lesions. Therefore, follow up is preferred to endoscopic resection in Japan

Lee SY. 2014

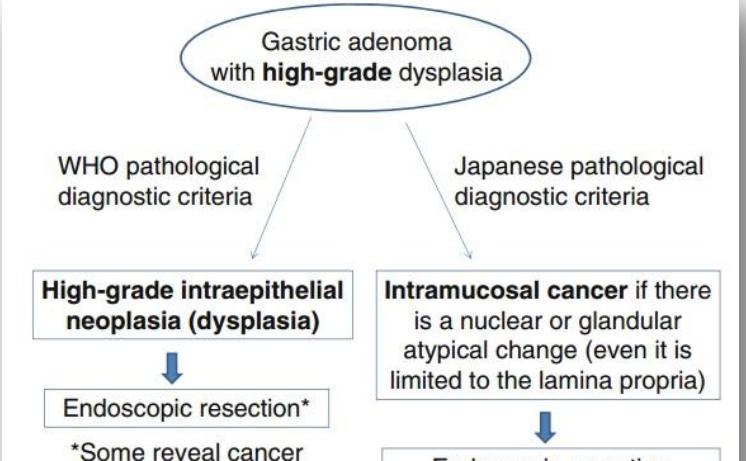

Fig. 3 Different diagnosis and management for gastric adenoma with high-grade dysplasia. Japanese pathologists are reluctant to use the term "high-grade dysplasia" for the gastric lesions, and therefore, it is often diagnosed as intramucosal carcinoma in Japan

Lee SY. 2014

♠ Korean endoscopists are treating a lot of patients with gastric adenomas, and some of them may be considered as well-differentiated gastric adenocarcinomas in Japan.

Problem 3: Inter-observer variation

- Referred due to adenoma with high grade dysplasia (M/71)

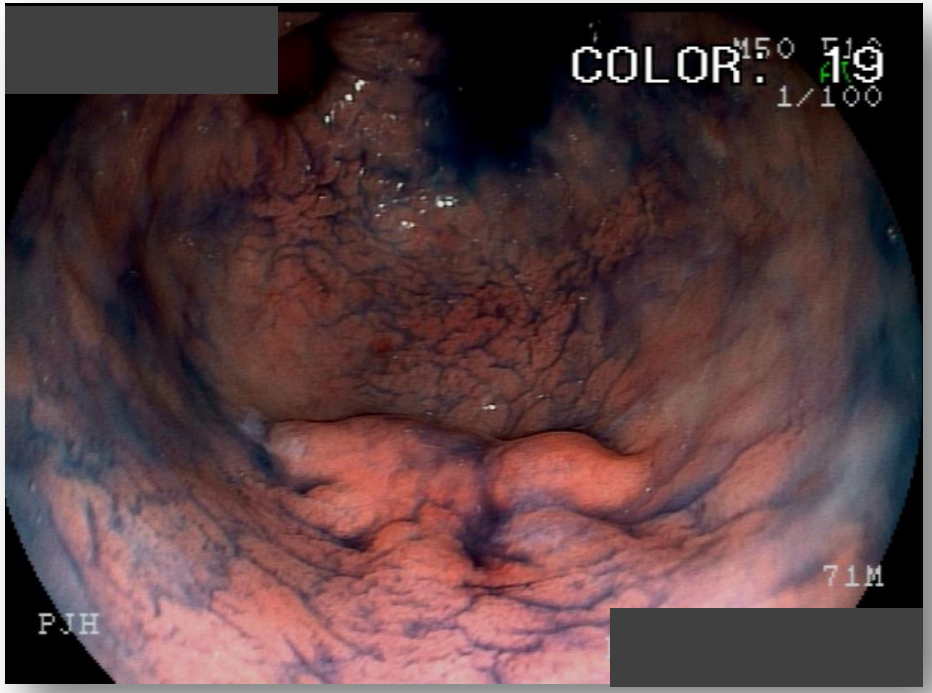

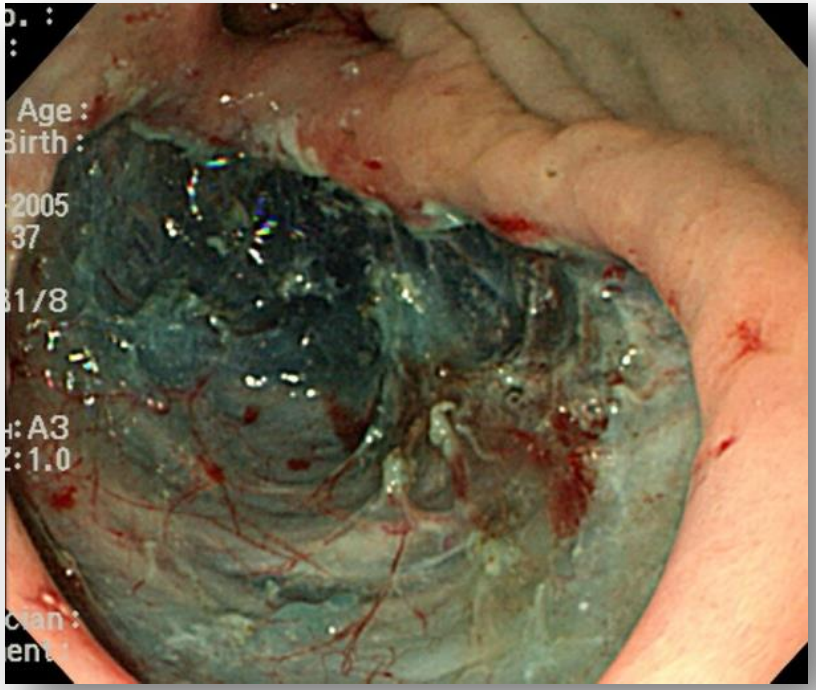

Outside biopsy slide review: adenocarcinoma (W/D)

Because of this kind of inter-observer variation, we always review the outside pathology slides before deciding initial treatment plan.

Do we have a firm understanding of the natural history?

Jun Haeng Lee. Department of Medicine
Sungkyunkwanuniversity School of Medicie, Seoul, Korea

History of gastric dysplasia

- from a very famous textbook

5 years
10%

5 years
10%

3 months – 2 years
50-90%

Mild Dysplasia → ← Moderate Dysplasia → ← High Grade Dysplasia ⇒ **Gastric Cancer**

60%

10%

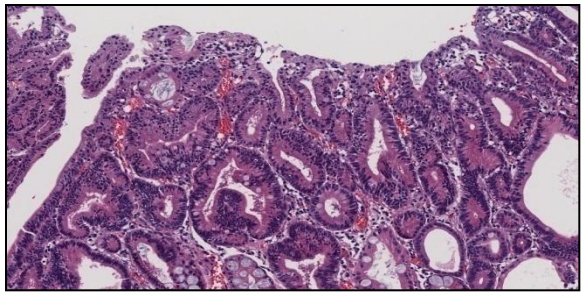

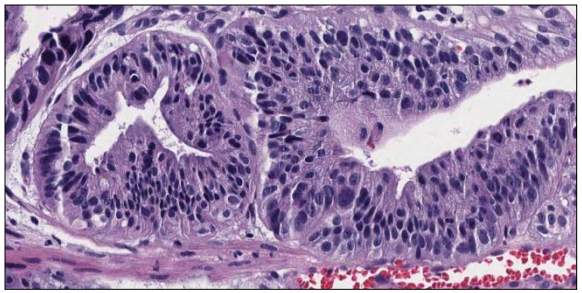

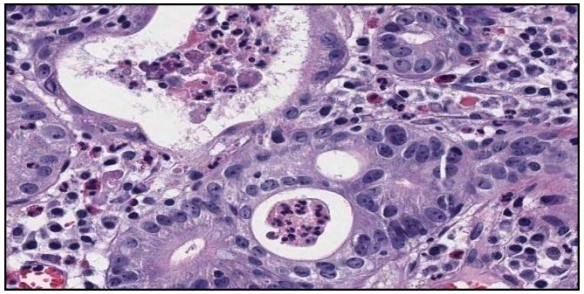

Luk GD. Sleisenger's. 6th ed. page 736

No change for 8 years

- Biopsy: adenoma with LGD

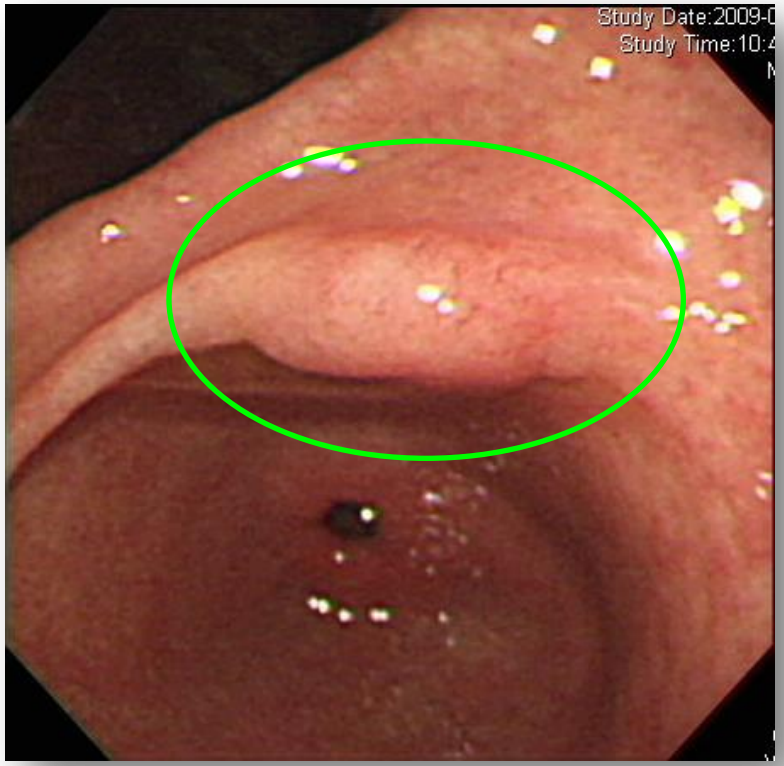

Progression to invasive carcinoma (cat 5)

- significant difference between authors

Author	LGD (Vienna category 3)		**HGD** (Vienna category 4)	
	% fraction	interval	% fraction	Interval
Saraga (1987)	2% (1/64)	4 years	81% (7/21)	4 months
Lansdown (1990)	0% (0/7)		85% (11/13)	5 months
Rugge (1991)	17% (12/69)	1 year	75% (6/8)	4 months
Fertitta (1993)	23% (7/30)	10 months	81% (25/31)	5 months
Di Gregorio (1993)	7% (6/89)	2 years	60% (6/10)	11 months
Rugge (1994)	14% (13/90)	2 years	78% (14/18)	9 months
Kokkola (1996)	0% (0/96)		67% (2/3)	1.5 year
Yamada (2004)	0% (0/38)		10% (1/10)	4.6 year

Is it true disease progression or under-evaluation due to small biopsy specimen?

Biopsy / Resected	LGD	HGD	Total
LGD	83	3	86
HGD	12	12	24
Carcinoma	**1**	**7**	**8**
Total	96	22	118

Park DI. Endoscopy 2001;33:501-506

Biopsy: adenoma with LGD
ESD specimen: W/D adenocarcinoma in lamina propria, 10x8 mm

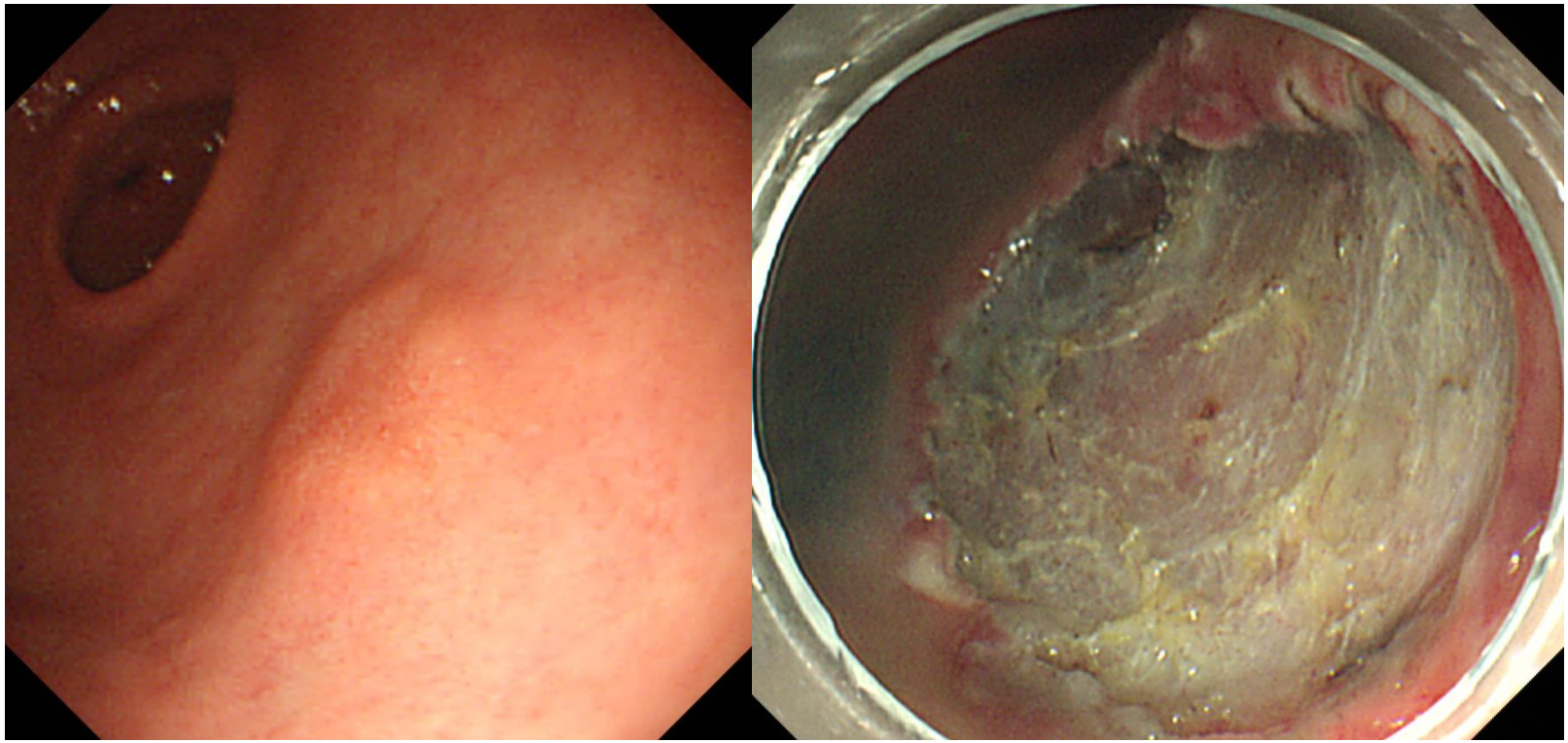

ESD/EMR for gastric adenoma

- A unique feature of endoscopic treatment of gastric neoplasms in Korea

Jun Haeng Lee. Department of Medicine

Sungkyunkwanuniversity School of Medicie, Seoul, Korea

Endoscopic or surgical resection of gastric neoplasms in SMC (2012)

- Excluding palliative surgeries

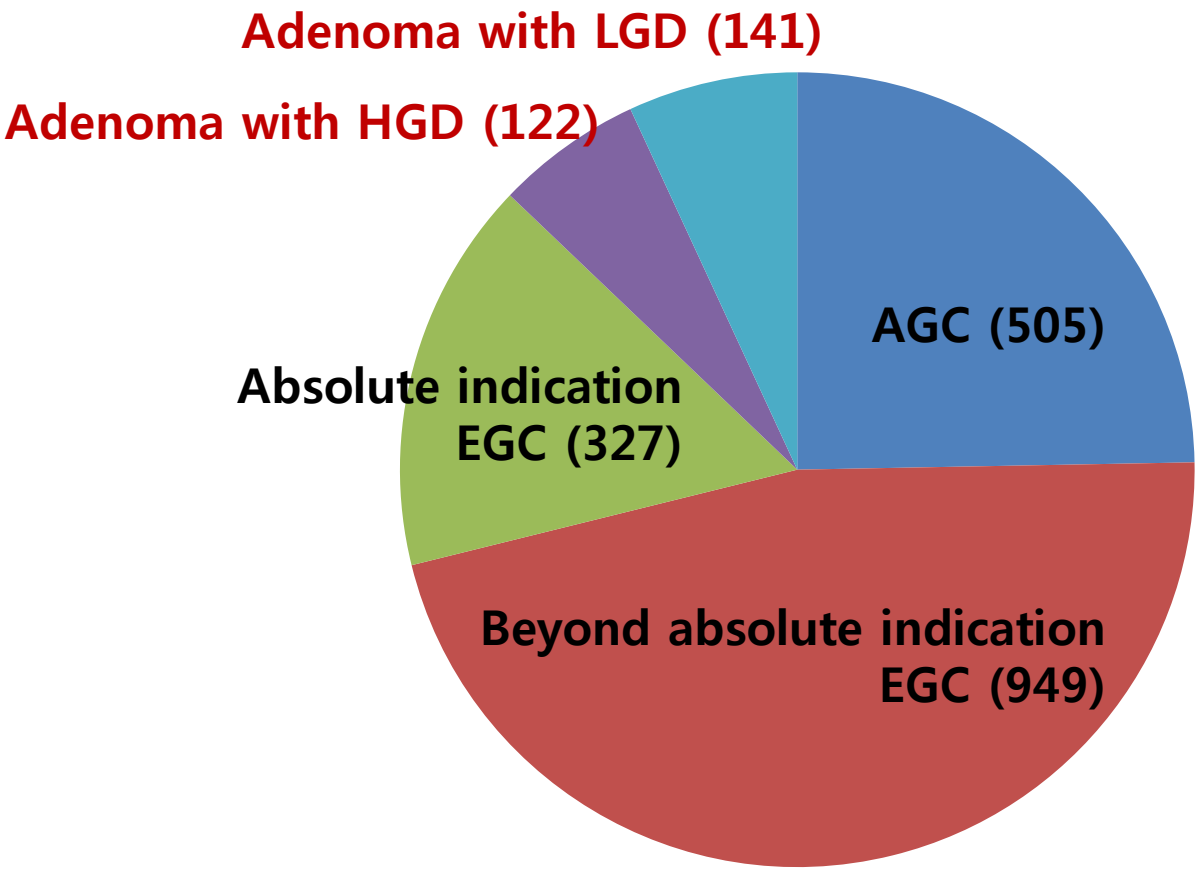

EGCs among all gastric cancers: 71.6% (327/1,781)
Absolute indication EGCs among all EGCs: 25.6% (327/1,276)

Diagnostic group classifications before and after the treatment

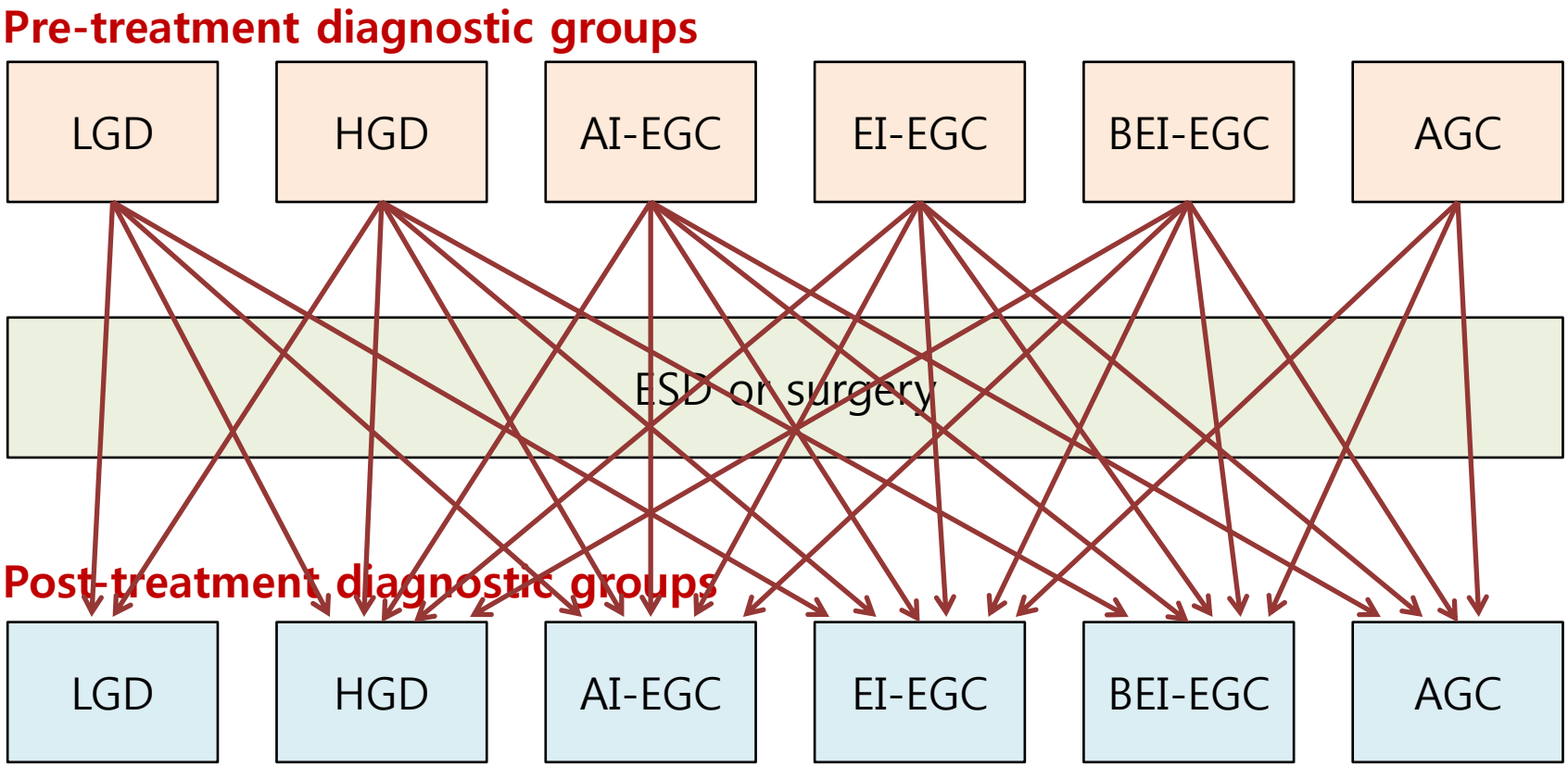

Absolute indication EGC by pre-treatment diagnostic groups

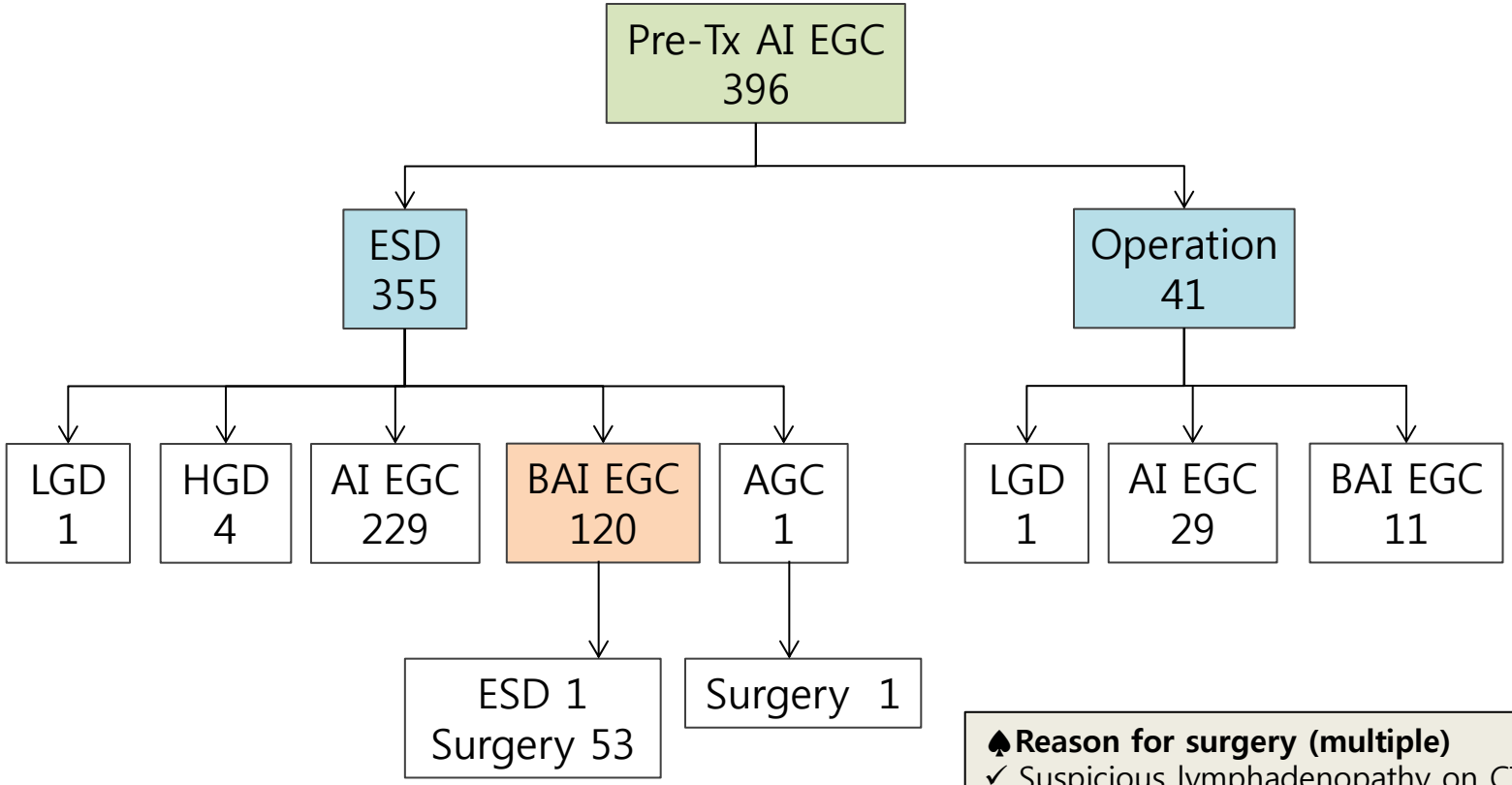

♠**Reason for surgery (multiple)**
- ✓ Suspicious lymphadenopathy on CT (18)
- ✓ Multiple lesions (6)
- ✓ Patient's wish (18)
- ✓ Difficult location (3)
- ✓ Suspicious SM invasion on EUS (2)

* BAI: beyond absolute indications

Lee JH. Surg Endosc 2016;30:3987-93

Discrepancy between pre- and post-treatment diagnosis, SMC (2012)

Table 1 Pretreatment and posttreatment diagnostic group classification for gastric dysplasias or cancers

Posttreatment diagnostic group	Pretreatment diagnostic group (%)				
	LGD (*n*=162)	HGD (*n*=164)	AI-EGC (*n*=396)	BAI-EGC (*n*=824)	AGC (*n*=495)
No residual	2 (1.2)	4 (2.4)	0	0	0
LGD	105 (64.8)	33 (20.1)	2 (0.5)	0	0
HGD	45 (27.8)	71 (43.3)	4 (1.0)	1 (0.1)	0
AI-EGC	5 (3.1)	36 (22.0)	258 (64.9)	22 (2.7)	1 (0.3)
BAI-EGC	5 (3.1)	19 (11.6)	131 (33.3)	720 (87.4)	72 (14.5)
AGC	0	1 (0.6)	1 (0.3)	81 (9.8)	422 (85.3)
Downgraded (%)	1.2	23.7	1.5	2.8	14.7
No change (%)	64.8	43.3	64.9	87.4	85.3
Upgraded (%)	34.0	34.1	33.6	9.8	0

LGD low-grade dysplasia, *HGD* high-grade dysplasia, *AI-EGC* absolute indication early gastric cancer, *BAI-EGC* beyond absolute indication early gastric cancer

Lee JH. Surg Endosc 2016;30:3987-93

Surgery was done before ESD era.

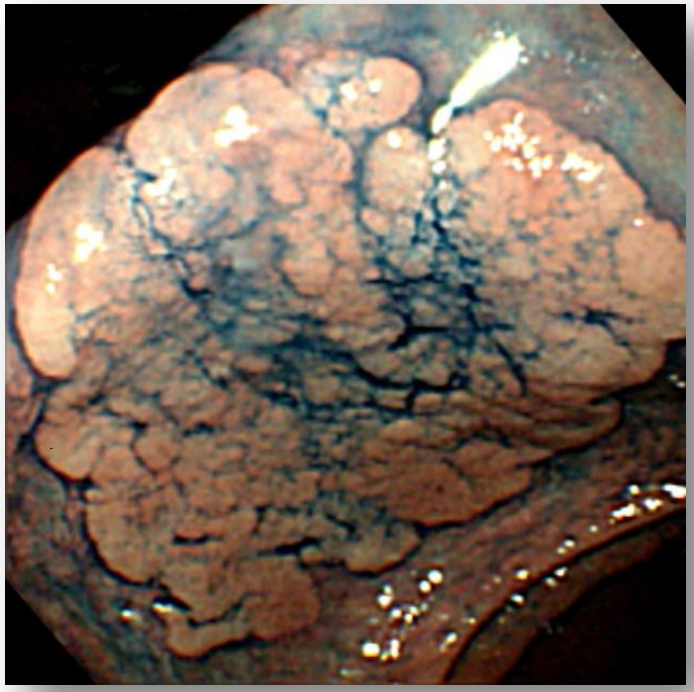

Villous adenoma with high grade dysplasia, 4.0x3.6cm

A majority of gastric adenoma is treated by ESD or EMR.

Tubular adenoma, elevated type, 4x3.5cm, negative RM

ESD for adenoma with LGD (IIa+IIc)

- Final pathology: adenoma with LGD, 1.4x1.2cm

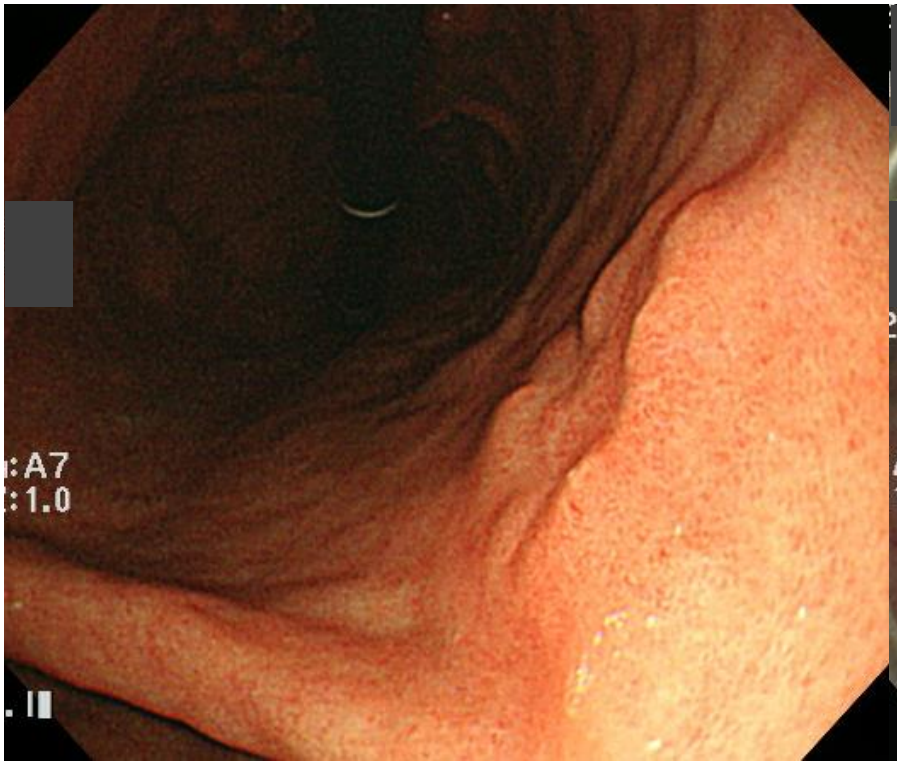

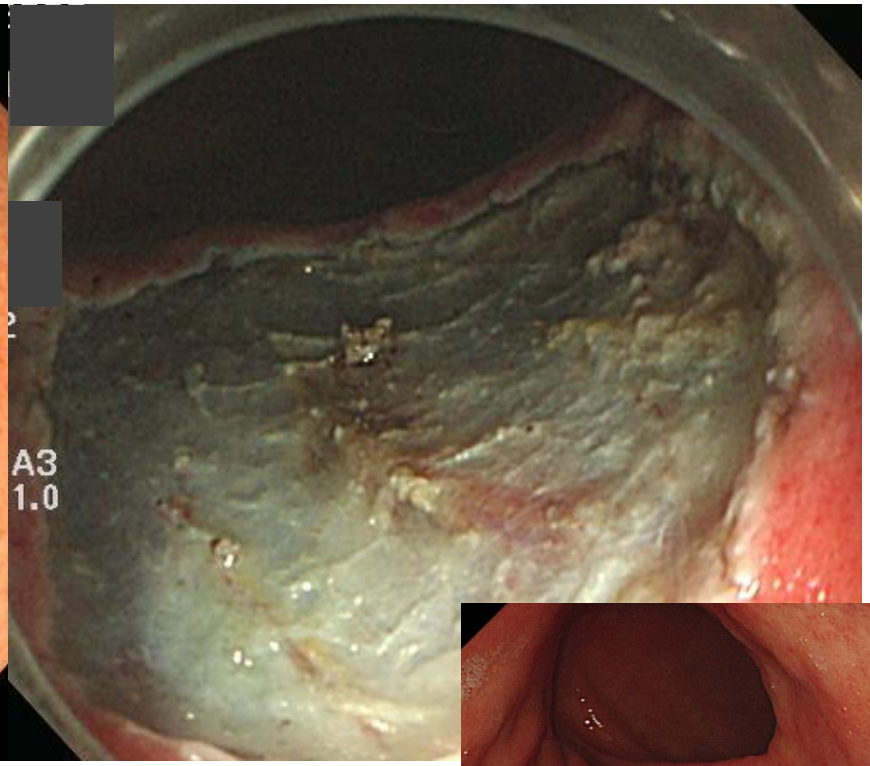

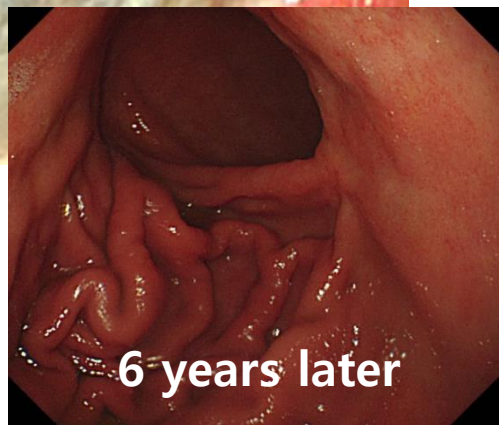

Consider ER for LGD, 2cm or more & don't have pale discoloration

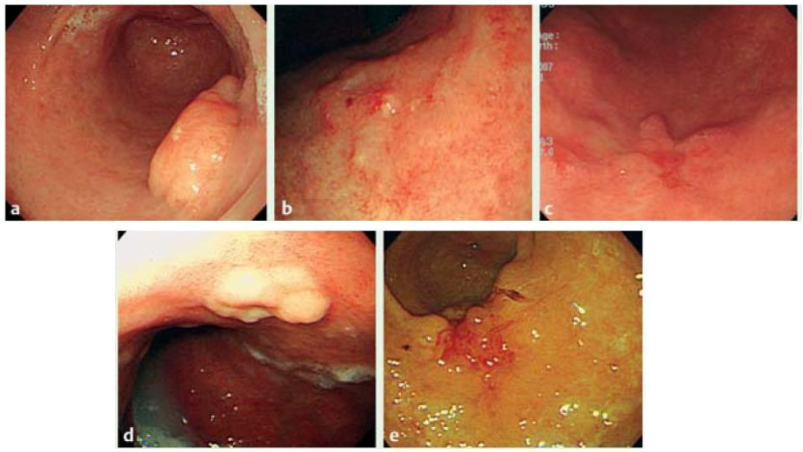

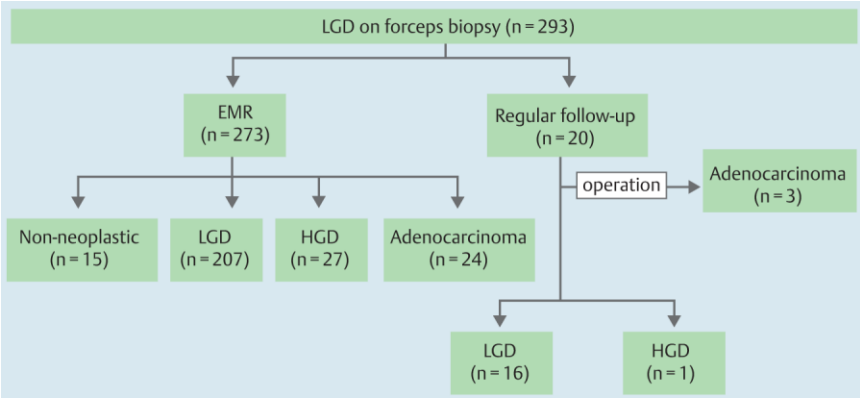

Table 3 Univariate analysis of baseline characteristics and endoscopic features in the concordant and the upgraded low-grade dysplastic lesions after endoscopic mucosal resection.

	Concordant (n = 207)	Upgraded (n = 51)	*P*-value
Age, years, mean ± SD (range)	62.9 ± 8.5 (39 – 87)	62.8 ± 9.9 (35 – 82)	0.918
Male sex, n (%)	169 (61.7)	57 (65.5)	0.407
Number of biopsy fragments, mean ± SD (range)	2.9 ± 1.4 (1 – 10)	3.3 ± 1.5 (1 – 7)	0.087
Lesion size, mm, mean ± SD (range)	12.3 ± 6.3 (4 – 50)	13.7 ± 9.3 (3 – 45)	0.081
Lesion size, n (%)			0.026
< 10 mm	60 (29.0)	11 (21.5)	
≥10 mm and < 20 mm	115 (55.6)	26 (51.0)	
≥ 20 mm and < 30 mm	28 (13.5)	8 (15.7)	
≥ 30 mm	4 (1.9)	6 (11.8)	
Lesion type, n (%)			0.126
Elevated	150 (72.5)	30 (58.8)	
Flat/depressed	57 (27.5)	21 (41.2)	
Whitish discoloration absent, n (%)	124 (59.1)	46 (90.2)	< 0.001
Spontaneous bleeding present, n (%)	7 (3.4)	6 (11.8)	0.025

Kim YJ, Lee YC (Yonsei U). Endoscopy 2010;42:620–626

Small, flat, and pale adenoma with low grade dysplasia is treated by ablation.

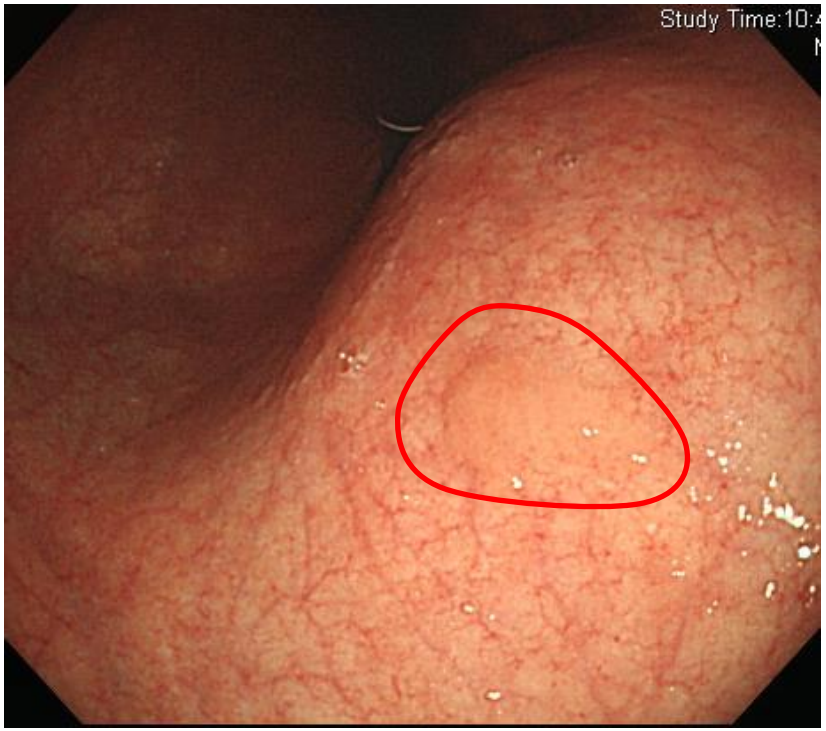

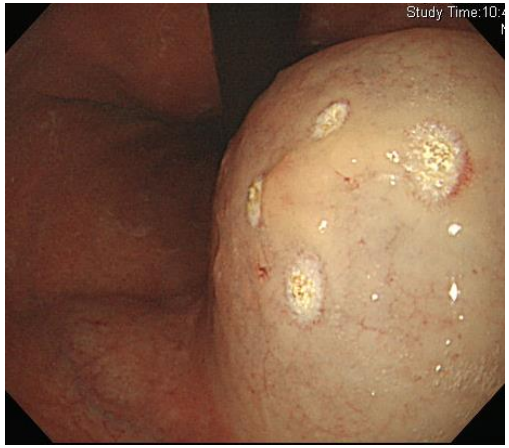

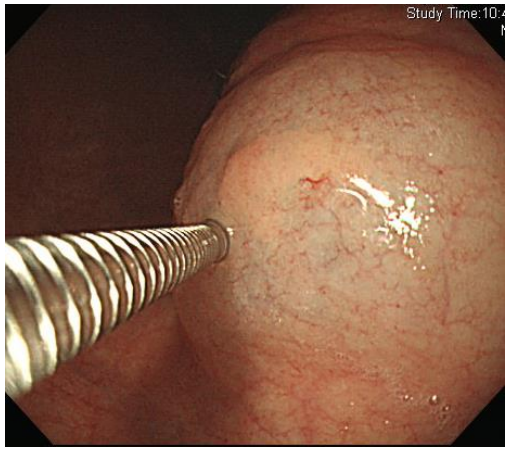

Take home message

- Adenomas with low grade dysplasia can be treated by either endoscopic ablation or resection depending on the clinical characteristics.
- Adenomas with high grade dysplasia should be resected due to the very high risk of cancer.

Thank you for your attention.