

# Diagnosis and Treatment Strategy of Achalasia Subtypes and Esophagogastric Junction Outflow Obstruction Based on High-Resolution Manometry

Eikichi Ihara Kazumasa Muta Keita Fukaura Kazuhiko Nakamura

Department of Medicine and Bioregulatory Science, Graduate School of Medical Sciences, Kyushu University, Fukuoka, Japan

## Key Words

Esophagogastric junction outflow obstruction · Achalasia · High-resolution manometry · Acotiamide

## Abstract

**Background:** Based on Chicago Classification version 3.0, the disorders of esophagogastric junction outflow obstruction (EGJOO) include achalasia (types I, II and III) and EGJOO. Although no curative treatments are currently available for the treatment of the disorders of EGJOO, medical treatments, endoscopic pneumatic dilation (PD), laparoscopic Heller myotomy (LHM), and per-oral endoscopic myotomy (POEM) are usually the sought-after modes of treatment. Since the etiology and pathogenesis might vary depending on the types of EGJOO disorders, treatment strategies should be considered based on those subtypes. **Summary:** Based on the accumulated evidences, the treatment strategies of our institution are as follows: effects of medical treatments on achalasia are limited. Either PD or LHM/POEM can be considered a first-line in achalasia type I, according to the patient's wish. PD and POEM can be considered first-line in achalasia types II and III, respectively. Conversely, In EGJOO, medical treatments including drugs like acotiamide and/or diltiazem can be tested as a first-line, and PD and POEM will be considered second and third-line treatments, respectively. **Key Messages:** The classification of subtypes based on high-resolution manometry will help us consider which

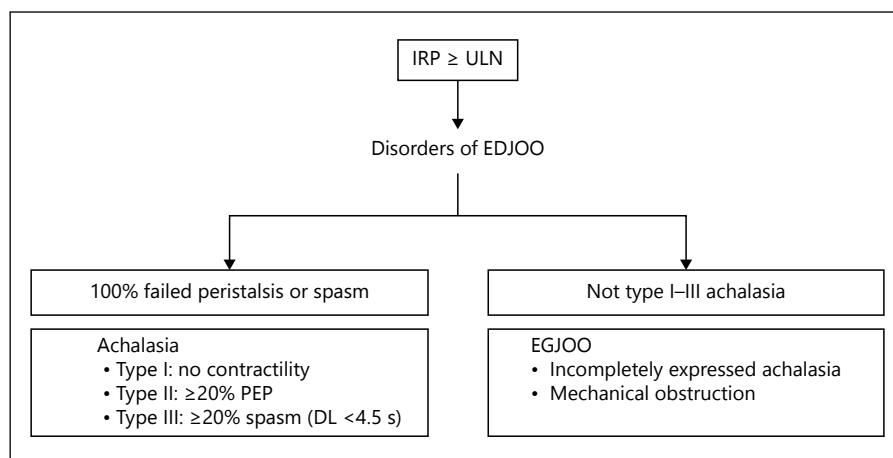
treatment option can be selected as a first-line treatment depending upon the subtypes of disorders of EGJOO. Acotiamide has the potential to cure patients with EGJOO.

© 2016 S. Karger AG, Basel

## Introduction

Sophisticated esophageal contractility plays an important role in maintaining the esophageal motility function. The recently developed high-resolution manometry (HRM) method allows us to evaluate esophageal motility function more precisely than conventional manometry. Based on Chicago Classification version 3.0 (CC ver3.0), major EMDs are divided into disorders of esophagogastric junction outflow obstruction (EGJOO) and major disorders of peristalsis [1]. The disorders of EGJOO, which are characteristics of impaired lower esophageal sphincter (LES) relaxation, include 2 entities – EGJOO and achalasia with or without preserved esophageal body peristalsis (fig. 1). Achalasia is further divided into 3 manometric subtypes: types I, II and III. Although no curative treatments are currently available for treating the disorders of EGJOO, medical treatments, endoscopic pneumatic dilation (PD), laparoscopic Heller myotomy (LHM), per-oral endoscopic myotomy (POEM) and botulinum toxin injection are usually the sought-after methods. Since the etiology and pathogenesis might vary de-

**Fig. 1.** Diagnosis of disorders of EGJOO according to CC ver3.0 (adapted from Collman et al. [3]). Disorders of EGJOO are classified into EGJOO and achalasia (types I, II and III), with or without esophageal body peristalsis, respectively. PEP = Panesophageal pressurization.



pending on the types of EGJOO disorders, treatment strategies should be considered based on those subtypes. This review focused on the current understanding of pathophysiology, diagnosis, and management of the disorders of EGJOO and we summarized the treatment strategies for achalasia subtypes and EGJOO.

### Classification of Disorders of EGJOO Based on HRM

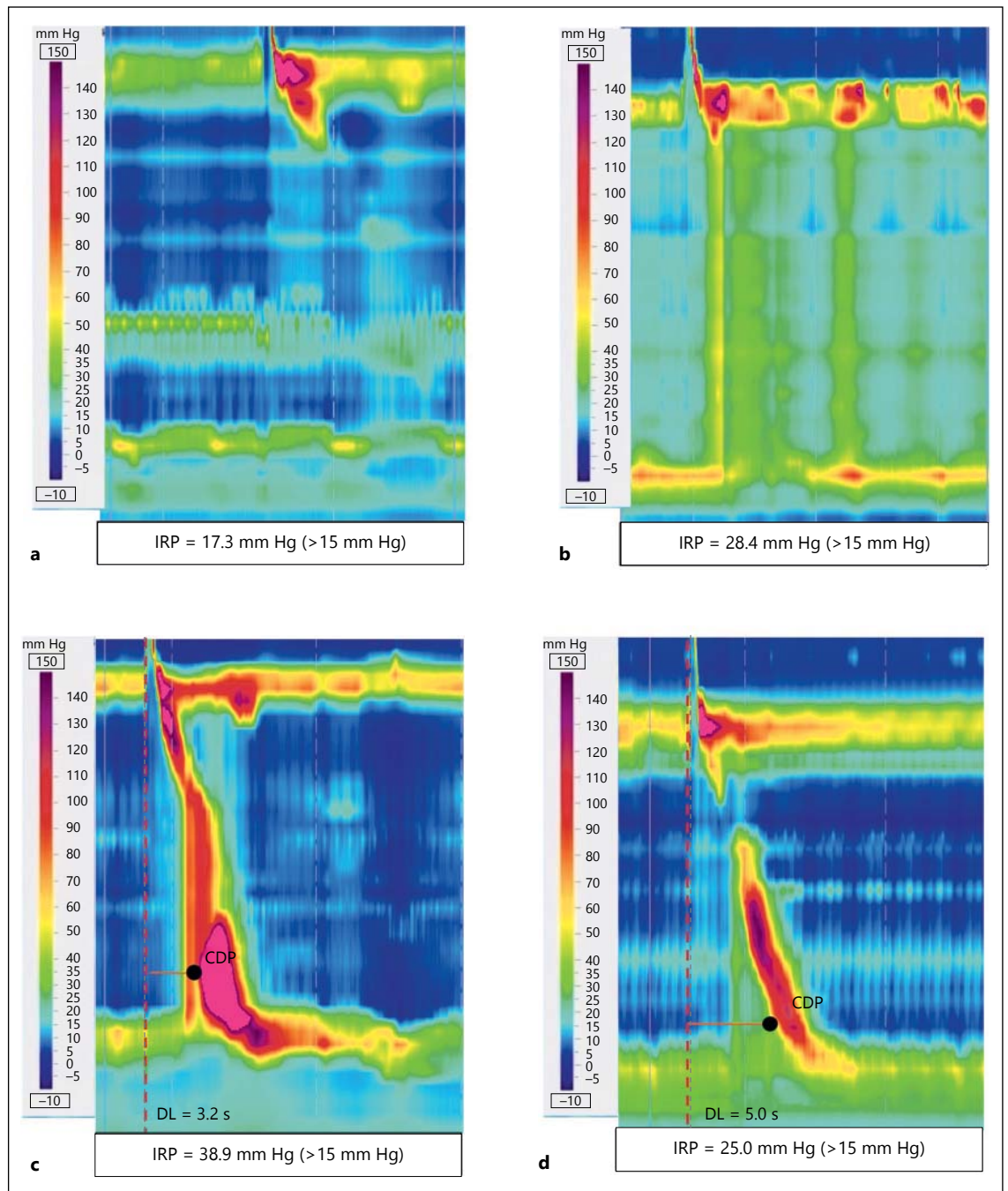
According to CC ver3.0, classification of disorders of EGJOO is shown in figure 1. Several pressure topography metrics are introduced in CC ver3.0 to classify disorders of EGJOO [1]. First, integrated relaxation pressure (IRP) is calculated as the mean of the 4 s of maximal deglutitive relaxation in the 10-second window beginning at the time of upper esophageal sphincter (UES) relaxation. IRP higher than the upper limit of normal (ULN) indicates impaired swallow-induced LES relaxation. Second, contractile deceleration point (CDP) is defined as the inflection point along 30 mm Hg isobaric contour at which propagation velocity slows, demarcating peristalsis from ampullary emptying. Third, distal latency (DL) was defined as the interval between UES relaxation and the CDP. Disorders of EGJOO are defined as  $IRP \geq ULN$ , and they are classified into 2 entities, achalasia and EGJOO, characterized by the absence and presence, respectively, of preserved peristalsis. Then, achalasia was further classified into 3 manometric subtypes based on the residual esophageal wave pattern [1]: type I is characterized by 100% failed contractions and no esophageal pressurization (fig. 2a); type II is defined as panesophageal pressurization occurring with at least 20% of swallows (fig. 2b); type III is defined as the presence of premature contrac-

tion for at least 20% of the swallow (fig. 2c) where premature contraction was defined as  $DL < 4.5$  s. In contrast, EGJOO is defined as  $IRP \geq ULN$  with some instances of intact or weak peristalsis such that the criteria of achalasia are not met (fig. 2d).

### The Proposed Etiology and Pathogenesis of Disorders of EGJOO

Esophagus has the unique muscular structure to achieve coordinated esophageal motility function with striated muscle of the proximal esophagus and smooth muscle of the distal esophagus. Importantly, the smooth muscle part of distal esophagus is further divided into 2 different portions: esophageal body phasic smooth muscle and LES tonic smooth muscle [2]. The smooth muscle of the distal esophagus is innervated by the pre-ganglionic vagus nerve fibers with cell bodies located in the dorsal motor nucleus [3]. The preganglionic neurons are cholinergic in nature and synapse on postganglionic excitatory cholinergic and inhibitory nitrenergic/VIP neurons in the myenteric plexus. Then, the opposing activities of excitatory and inhibitory vagal pathways play a role in coordinating the esophageal body phasic smooth muscle contractility. In contrast, LES tonic smooth muscle owns myogenic tone and it spontaneously develops and maintains a basal tone. As a result, LES pressure is determined by the net balance of activities among myogenic tone, cholinergic excitatory and nitrenergic/VIP inhibitory nerve fibers.

In the initial stage of achalasia, degeneration of inhibitory nerve fibers in the myenteric plexus occurs, resulting in losing control of activity of excitatory nerve fibers



**Fig. 2.** Representative HRM findings for disorders of EGJOO. **a–d** Representative HRM finding of achalasia type I (**a**), type II (**b**), type III (**c**) and EGJOO (**d**).

and leading to high amplitude non-peristaltic contractions [4]. It has been shown that nitroergic neurons are significantly decreased in esophageal myenteric plexus in patients with achalasia [5]. In normal subjects, liquid stimulation of pharynx (pharyngeal water stimulation; PWS) induces relaxation of LES and inhibition of esoph-

ageal body peristalsis [6], which is indispensable for coordinated esophageal motility function. In the initial stage of achalasia, due to the alteration of those inhibitory responses, impaired LES relaxation is accompanied by premature esophageal body contraction defined by DL <4.5 s. These situations are considered to cause types III

or II achalasia depending on the extent of loss of inhibitory nerve fibers. In contrast, it is thought that progression of the disease causes not only loss of inhibitory nerve fibers but also excitatory nerve fibers. In the end stage of the disease, enteric nerve innervation is completely diminished, while only myogenic tone regulation of LES remains to survive. This condition of the disease could correspond to type I achalasia, characteristics of which are impaired LES relaxation and absent peristalsis. Although the precise etiologies and pathogenesis of achalasia have not been fully determined, achalasia is considered to be multi-factorial, with autoimmune mechanisms triggered by infection in a genetically predisposed individual, thereby leading to the degeneration of enteric ganglia in the wall of the esophagus [4]. The distinct phenotypes of achalasia may be associated with certain immunotoxicity patterns. Specifically, the cytotoxic immune response leading to aganglionosis is responsible for types I/II achalasia, whereas the non-toxic immune response that does not cause progression to aganglionosis is responsible for type III achalasia [7].

On the other hand, little is known about the etiologies and pathogenesis of EGJOO since it is a relatively new clinical entity. EGJOO is characterized by impaired swallow-induced LES relaxation in combination with preserved peristalsis. We have recently shown that one of the important pathogenesis of EGJOO might be alteration of PWS-induced LES relaxation although the response of liquid swallow-induced LES relaxation itself is still almost preserved in EGJOO [8]. In addition, it seems that PWS-induced inhibition of esophageal body contractility contributes to preserve esophageal body peristalsis achieving DL >4.5 s in EGJOO. Although it is totally unknown why only PWS-induced LES relaxation is altered in EGJOO but both esophageal body peristalsis and liquid swallow-induced LES relaxation were still preserved, it is considered that EGJOO is likely a variant of achalasia or its early stage. In fact, it was suggested that EGJOO may be a precursor condition of both types I/II and III achalasia [7].

### **Treatment Strategies for Achalasia Based on Subtypes**

No curative treatments are currently available for treating achalasia. Since etiology and pathogenesis vary by types I, II and III achalasia, treatment strategies will be considered based on the subtypes of achalasia. Both L type Ca<sup>2+</sup> channel blockers and NO derivatives are options for medical treatments, but they might have inhibitory effects on

LES pressure; however, those effects are limited in patients with achalasia. Basically, thus, the endoscopic (PD) or surgical (LHM) treatment will be usually considered. PD is an endoscopic procedure that extends LES by a cylindrical balloon ranging from 30 to 40 mm in diameter, inflated with air using a handheld manometer. LHM is the standard surgical procedure that divides the circular muscle fibers of the LES. As for procedure-related complications, recent meta-analysis has shown that when PD is performed by experienced physicians using modern techniques, the incidence of perforation from PD is less than 1%, which is equivalent to the risk of unrecognized perforation during Heller myotomy [9]. It has been reported that patients with achalasia have a variable prognosis after PD or LHM based on subtypes. Patients with type II achalasia have a very favorable outcome (96%); type I achalasia has intermediate prognosis (81%), while type III achalasia has less favorable outcomes (66%) [10, 11]. In addition, it was reported that treatment success rate of PD (100%) was significantly higher than that of LHM (93%) for patients with type II achalasia, while the success rate of LHM (86%) tended to be significantly higher than that of PD (40%) in type III achalasia. In contrast, there was no significant difference in the success rate between PD and LHM in type I achalasia [11].

On the other hand, POEM is the recently developed treatment for esophageal motility disorders including achalasia [12]. The procedure requires making a small mucosal incision in the mid-esophagus and creating a submucosal tunnel all the way to the gastric cardia using a forward-viewing endoscope with insufflation of carbon dioxide. Selective myotomy of the circular muscle is achieved with an electrical knife. Currently, it is believed that the POEM is comparable with LHM in terms of safety and effectiveness when it comes to treating achalasia [13]. One of important advantages of POEM over LHM will be that POEM enables us to create a longer length of myotomy than LHM, which exerts a pronounced effect especially on type III achalasia. It has shown that more than 90% of patients with type III achalasia were successfully cured by POEM with appropriate length of myotomy. Since POEM was first performed in Japan for resolving uncomplicated achalasia, its excellent outcomes allowed us to expand the range of disorders to include advanced sigmoid achalasia, failed surgical myotomy and even other spastic esophageal motility disorders [14] such as distal esophageal spasm [15] and Jackhammer esophagus [16]. The outcome of POEM for achalasia remains excellent up to 3 years after operation [12]. Although information on the long-term outcome of this procedure is awaited, it is likely that POEM might replace LHM in the

**Table 1.** The outcomes of present treatments for disorders of EGJOO

	Pharmacological treatment	PD, %	Myotomy, %	Botulinum toxin injection
Achalasia type I	Little effect	85	81	Limited effects
Achalasia type II	Little effect	100	93	Limited effects
Achalasia type III	Little effect	40	86	Limited effects
EGJOO	50% (conventional) 83.3% (acotiamide)	33–100	100	100%

The success rate of each treatment (%) was created based on references [8, 10, 11, 17, 18].

**Table 2.** Proposed treatment strategies for disorders of EGJOO

	1st line	2nd line	3rd line
Achalasia type I	Pneumatic dilatation POEM/LHM	POEM	
Achalasia type II	Pneumatic dilatation	POEM/LHM	
Achalasia type III	POEM		
EGJOO	Medical treatments (acotiamide/diltiazem)	Pneumatic dilatation	POEM

future. Another option of treatment for achalasia is injecting botulinum toxin into the LES. It is thought that botulinum toxin reduced LES pressure mediated by inhibiting excitatory cholinergic nerves via blocking acetylcholine release from enteric nerve endings. In general, botulinum toxin injection should not be used as a first-line treatment for achalasia since the effect is temporary and in most patients there is a relapse of this condition. It can be used for patients on whom other definitive treatments cannot be applied because of their poor general medical conditions. The outcome of each treatment based on achalasia subtypes was summarized in table 1.

Based on the accumulated evidences mentioned above, the treatment strategies for achalasia currently performed in our institution are as follows (table 2): for the patients with type I achalasia, either PD or POEM/LHM is selected as a first-line treatment according to the patient's wish. In case PD is selected as a first-line treatment and, if any, treatment effects are not satisfactory, POEM/LHM will be considered second-line. As for achalasia type II, PD is selected as a first-line, considering a balance between efficacy and safety. Then, POEM/LHM will be selected as a second-line for the patients resistant to PD. As for achalasia type III, POEM is considered a first-line treatment.

### Treatment Strategies for EGJOO

No curative treatments are currently available even for EGJOO. It is reasonable that noninvasive medical treatments of option for EGJOO will be L type  $Ca^{2+}$  channel blockers and NO derivatives since both of them are commonly used for treatments of achalasia. Unfortunately, however, effects of those medical treatments are also limited in EGJOO patients with some degree of symptoms. It was reported that only 50% of EGJOO patients responded to pharmacological treatments [17]. EGJOO patients, resistant to medical treatments, may undergo invasive treatments inasmuch as EGJOO may be a variant of achalasia. It has been reported that 100% of those EGJOO patients were successfully treated by any type of invasive treatments including PD, botulinum toxin injection or surgery [17]. In another study, 100% response was obtained by botulinum toxin injection, while only 33% response was obtained by PD [18]. Although the favorable outcomes will usually be obtained by the invasive treatments, importantly one-third of the EGJOO patients presented a spontaneous resolution of symptoms without EGJOO treatments [17]. The invasive treatment, thus, should be considered with special caution. While more effective medical treatments will, thus, be awaited, we

have recently reported that acotiamide hydrochloride (acotiamide) has the potential to cure patients with EGJOO [8]. Acotiamide is a newly developed prokinetic drug that has been approved for the treatment of functional dyspepsia (FD) [19]. Acotiamide exerts prokinetic activity and improved impaired gastric emptying [20], essentially by acting as an AChE inhibitor or as an antagonist of M<sub>1</sub> and M<sub>2</sub> muscarinic receptors. It has also been found to improve gastric accommodation, which is impaired in patients with FD [19]. As mentioned above, PWS-induced LES relaxation was impaired in patients with EGJOO, and this impairment was successfully repaired by acotiamide. It has been shown that 83.3% of EGJOO patients with some degree of symptoms were successfully treated by acotiamide, which improved not only symptoms but also normalized the IRP level [8]. PWS-induced LES relaxation could be referred to as LES accommodation. Enhanced LES accommodation by acotiamide were similar to improvements observed in impaired proximal stomach accommodation in FD patients, given that LES exhibits characteristics of tonic contraction, similar to the proximal stomach. The outcome of each treatment for EGJOO was summarized in table 1 and the treatment strategies for EGJOO currently performed in our institution are shown in table 2. Medical treatments including acotiamide and/or diltiazem are considered a first-line treatment, and PD and POEM will be selected as second and third-line treatments, respectively.

## References

- 1 Kahrilas PJ, Bredenoord AJ, Fox M, Gyawali CP, Roman S, Smout AJ, Pandolfino JE: The Chicago Classification of esophageal motility disorders, v3.0. *Neurogastroenterol Motil* 2015;27:160–174.
- 2 Harnett KM, Cao W, Biancani P: Signal-transduction pathways that regulate smooth muscle function I. Signal transduction in phasic (esophageal) and tonic (gastroesophageal sphincter) smooth muscles. *Am J Physiol Gastrointest Liver Physiol* 2005;288:G407–G416.
- 3 Collman PI, Tremblay L, Diamant NE: The central vagal efferent supply to the esophagus and lower esophageal sphincter of the cat. *Gastroenterology* 1993;104:1430–1438.
- 4 Ghoshal UC, Daschakraborty SB, Singh R: Pathogenesis of achalasia cardia. *World J Gastroenterol* 2012;18:3050–3057.
- 5 Park W, Vaezi MF: Etiology and pathogenesis of achalasia: the current understanding. *Am J Gastroenterol* 2005;100:1404–1414.
- 6 Bardan E, Saeian K, Xie P, Ren J, Kern M, Dua K, Shaker R: Effect of pharyngeal stimulation on the motor function of the esophagus and its sphincters. *Laryngoscope* 1999;109:437–441.
- 7 Kahrilas PJ, Boeckxstaens G: The spectrum of achalasia: lessons from studies of pathophysiology and high-resolution manometry. *Gastroenterology* 2013;145:954–965.
- 8 Muta K, Ihara E, Fukaura K, Tsuchida O, Ochiai T, Nakamura K: Effects of acotiamide on the esophageal motility function in patients with esophageal motility disorders: a pilot study. *Digestion* 2016;94:9–16.
- 9 Lynch KL, Pandolfino JE, Howden CW, Kahrilas PJ: Major complications of pneumatic dilation and Heller myotomy for achalasia: single-center experience and systematic review of the literature. *Am J Gastroenterol* 2012;107:1817–1825.
- 10 Pandolfino JE, Gawron AJ: Achalasia: a systematic review. *JAMA* 2015;313:1841–1852.
- 11 Rohof WO, Salvador R, Annesse V, Bruley des Varannes S, Chaussade S, Costantini M, Elizalde JI, Gaudric M, Smout AJ, Tack J, Busch OR, Zaninotto G, Boeckxstaens GE: Outcomes of treatment for achalasia depend on manometric subtype. *Gastroenterology* 2013;144:718–725; quiz e13–e14.
- 12 Inoue H, Sato H, Ikeda H, Onimaru M, Sato C, Minami H, Yokomichi H, Kobayashi Y, Grimes KL, Kudo SE: Per-oral endoscopic myotomy: a series of 500 patients. *J Am Coll Surg* 2015;221:256–264.
- 13 Bhayani NH, Kurian AA, Dunst CM, Sharata AM, Rieder E, Swanstrom LL: A comparative study on comprehensive, objective outcomes of laparoscopic Heller myotomy with per-oral endoscopic myotomy (POEM) for achalasia. *Ann Surg* 2014;259:1098–1103.
- 14 Bechara R, Ikeda H, Inoue H: Peroral endoscopic myotomy: an evolving treatment for achalasia. *Nat Rev Gastroenterol Hepatol* 2015;12:410–426.
- 15 Sharata AM, Dunst CM, Pescarus R, Shlomovitz E, Wille AJ, Reavis KM, Swanstrom LL: Peroral endoscopic myotomy (POEM) for esophageal primary motility disorders: analysis of 100 consecutive patients. *J Gastrointest Surg* 2015;19:161–170; discussion 170.

## Conclusion

Although the etiology and pathogenesis of disorders of EGJOO are yet to be determined, they are classified into achalasia subtypes and EGJOO according to CC ver3.0. The etiology and pathogenesis might vary among achalasia subtypes and EGJOO. Since no curative treatments are currently available, the classification of subtypes based on HRM will help us to consider suitable treatment options based on the subtype of disorders of EGJOO. In these situations, acotiamide has the potential to cure patients with EGJOO.

## Author Contributions

E.I. and K.M. wrote the manuscript. Both K.M. and K.F. performed HRM. K.N. critically revised the manuscript for ensuring accuracy of content.

## Funding

The corresponding author was supported by the Japan Society for the Promotion of Science KAKENHI (26460940).

## Disclosure Statement

The authors declare that they have no conflicts of interest.

- 16 Bechara R, Ikeda H, Inoue H: Peroral endoscopic myotomy for jackhammer esophagus: to cut or not to cut the lower esophageal sphincter. *Endosc Int Open* 2016;4:E585–E588.
- 17 Perez-Fernandez MT, Santander C, Marinero A, Burgos-Santamaria D, Chavarria-Herbozo C: Characterization and follow-up of esophago-gastric junction outflow obstruction detected by high resolution manometry. *Neurogastroenterol Motil* 2016;28:116–126.
- 18 van Hoeij FB, Smout AJ, Bredenoord AJ: Characterization of idiopathic esophago-gastric junction outflow obstruction. *Neurogastroenterol Motil* 2015;27:1310–1316.
- 19 Kusunoki H, Haruma K, Manabe N, Imamura H, Kamada T, Shiotani A, Hata J, Sugioka H, Saito Y, Kato H, Tack J: Therapeutic efficacy of acotiamide in patients with functional dyspepsia based on enhanced postprandial gastric accommodation and emptying: randomized controlled study evaluation by real-time ultrasonography. *Neurogastroenterol Motil* 2012;24:540–545, e250–e251.
- 20 Kawachi M, Matsunaga Y, Tanaka T, Hori Y, Ito K, Nagahama K, Ozaki T, Inoue N, Toda R, Yoshii K, Hirayama M, Kawabata Y, Takei M: Acotiamide hydrochloride (Z-338) enhances gastric motility and emptying by inhibiting acetylcholinesterase activity in rats. *Eur J Pharmacol* 2011;666:218–225.