

\*

. . . . . \* . \*

= Abstract =

**Two Cases of Unilateral Transient Sialoadenopathy after Gastroscopy**

**Chang Young Lee, M.D., Suck Jang, M.D., Jung Sik Park, M.D.  
Byung Gon Jung, M.D., Ji Gyeom Kim, M.D., Young Kweon Paek, M.D.  
Hyang Ju Lee, M.D., Ho Jung Kim, M.D., Dae Sup Choi, M.D.  
Dae Chul Chun, M.D.\* and Jong Suk Kim, M.D.\***

Department of Internal Medicine, SungAe General Hospital, Seoul;  
\*Department of Internal Medicine, KwangMyung-SungAe General Hospital,  
Kwangmyung, Korea

A case was experienced involving submandibular salivary gland swelling (sialoadenopathy), developing after gastroscopy in a 15-year-old female who was suffering from epigastric pain & diarrhea and a case of parotid salivary gland swelling after gastroscopy in a 25-year-old female who was suffering from dyspepsia and epigastric pain. Both patients were the first two cases among about 5,000 gastroscopic examinations of the stomach conducted by the authors. As soon as the gastroscope was withdrawn, unilateral swelling, which was neither painful nor tender, was found in the left submandibular salivary gland area. This swelling disappeared spontaneously in about few hours later. (Korean J Gastrointest Endosc 19: 935-938, 1999)

**Key Words:** Sialoadenopathy, Submandibular salivary gland, Gastrofiberscopy

Palmer Boycel) (1964)  
Slaughter Boyce2) (1969)가

: 1998 6 24 , : 1999 5 18  
: , 1 451-5  
: 150-051,  
Tel: 840-7639, Fax: 840-7755



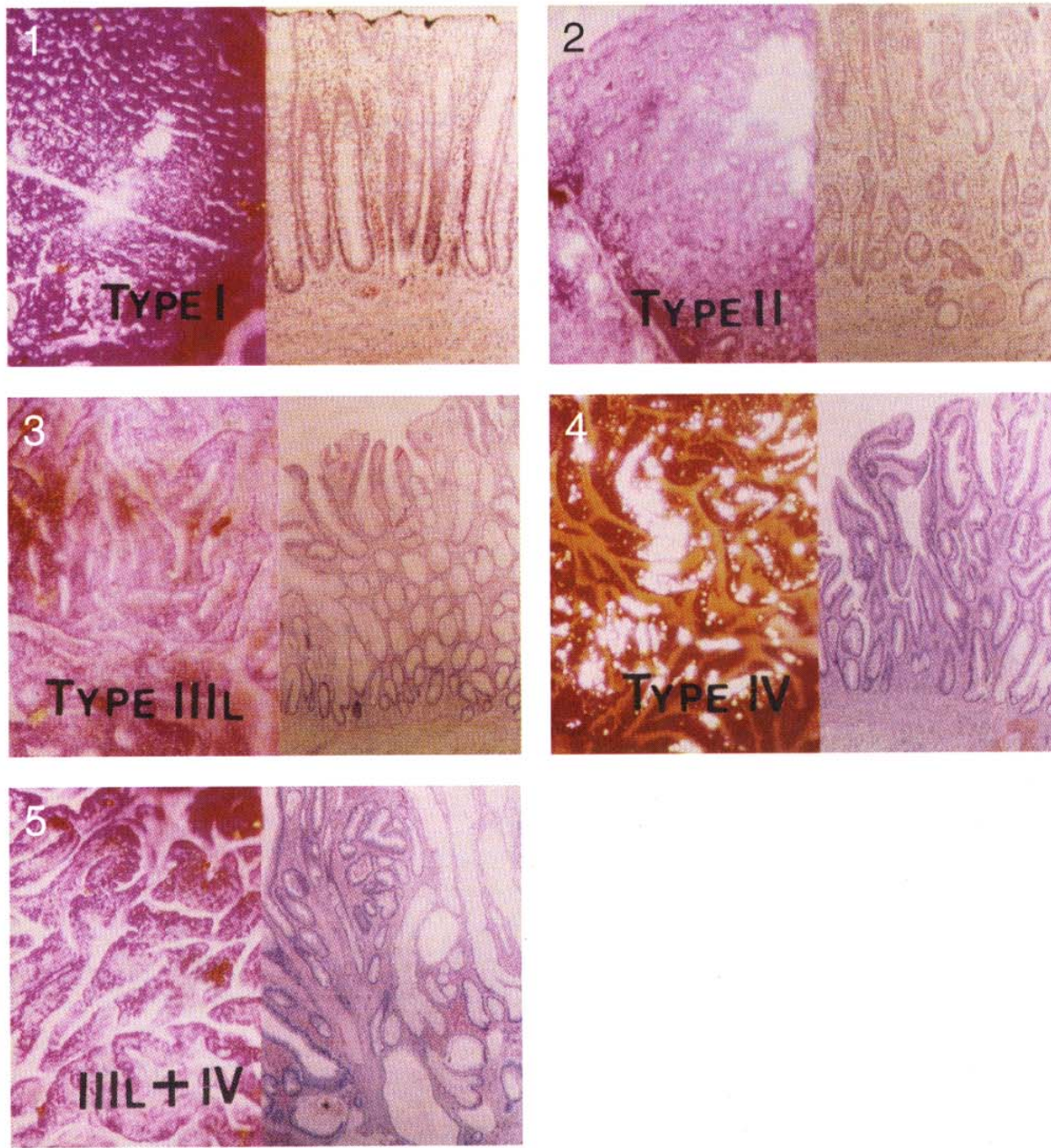


- 2
- 1) Palmer ED, Boyce HW Jr: Manual of gastrointestinal endoscopy. Williams & Wilkins: Baltimore 1964
  - 2) Slaughter RL, Boyce HW Jr: Submaxillary salivary gland swelling developing during peroral endoscopy. Gastroenterology 57: 83, 1969
  - 3) Blackford RW: Recurrent swelling of the parotid and submaxillary glands following bronchoscopy. Ann Otol Rhinol Laryngol 53: 54, 1944
  - 4) Attas M, Sabawla PB, Keats AS: Acute transient sialoadenopathy during induction of anesthesia. Anesthesiology 29: 1050, 1968
  - 5) Bonchek LI: Salivary gland enlargement during induction of anesthesia. JAMA 209: 1716, 1969
  - 6) Gupta R: Unilateral transient sialadenopathy: another complication of oropharyngeal airway. Anesthesiology 88: 551, 1998
  - 7) , : 1 . 4: 59, 1972
  - 8) Slaughter RL: Parotid gland swelling developing during peroral endoscopy. Gastrointest Endosc 22: 38, 1975
  - 9) Shields HM, Soloway RD, Long WB, Weiss JB: Bilaterally recurrent parotid gland swelling after endoscopy. Gastroenterology 73: 164, 1977
  - 10) , , , : 5 . 14: 409, 1994
  - 11) Maynard JP: Recurrent parotid enlargement. Br J Surg 52: 784, 1965
  - 12) Matsuki M: The acute onset of facial oedema after extubation. Anesthesia 37: 596, 1982
  - 13) Gombar KK, Singh B: Bilateral parotid sialadenopathy associated with general anesthesia. J Oral Maxillofac Surg 51: 328, 1993
  - 14) Smith GL, Mainous EG, Crowell NT: Unilateral submandibular gland swelling after induction of general anesthesia: report of case. J Oral Surg 30: 911, 1972
  - 15) Couper JL: Benign transient enlargement of the parotid glands associated with anaesthesia. Sou Afr Med J 47: 316, 1973
  - 16) Conacher ID: Acute onset facial oedema - a complication of extubation. Anaesthesia 36: 45, 1981
  - 17) Jeffrey B: Bilateral parotid sialadenopathy associated with general anesthesia. J Oral Maxillofac Surg 51: 330, 1993

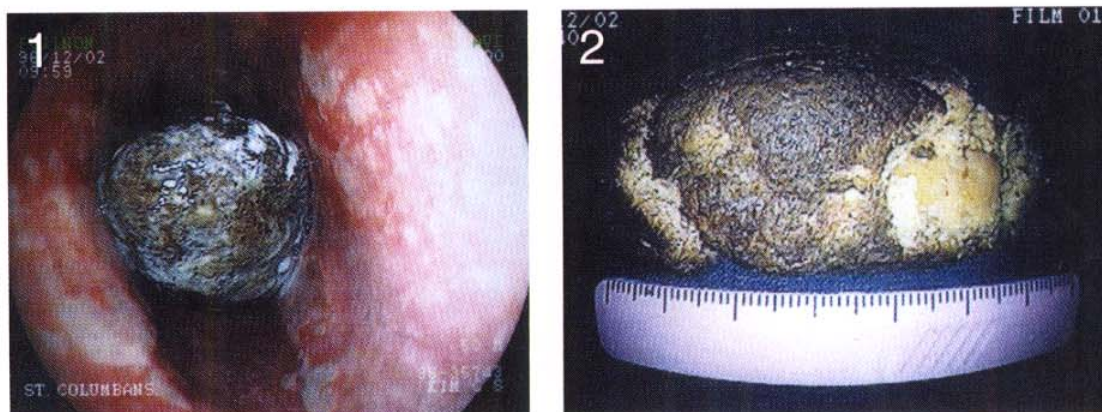---

**Fig. 1.** The patient showing swelling of submandibular glands approximately 30 min after gastroscopy.

◇ 강남용 외 9인 논문사진(본문게재 : 904~910쪽) ◇



◇ 윤태용 외 8인 논문사진(본문게재 : 930~934쪽) ◇



◇ 이창영 외 10인 논문사진(본문게재 : 935~938쪽) ◇

