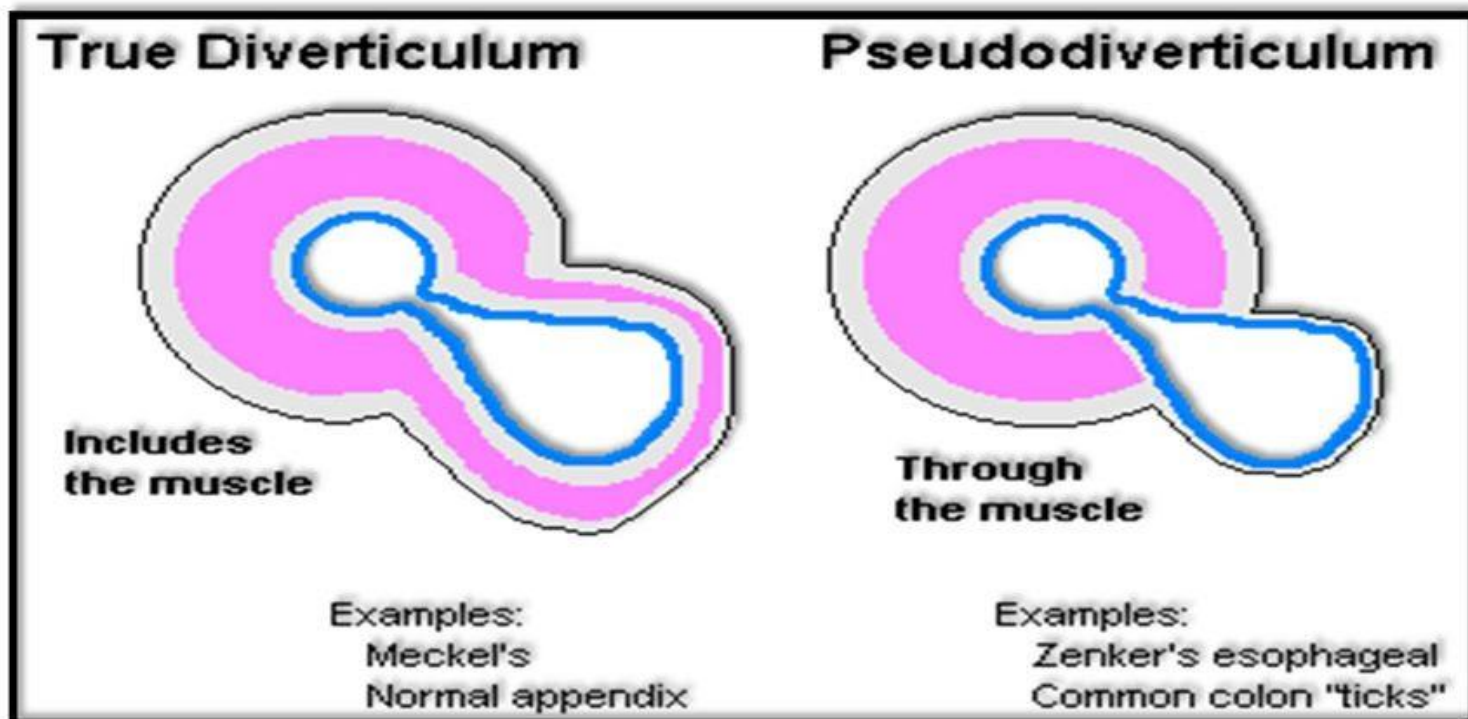


Colonic Diverticular Bleeding

F 표정의

What exactly is a diverticulum?

- Colonic diverticulosis is actually not a true diverticulum but rather a pseudo-diverticulum



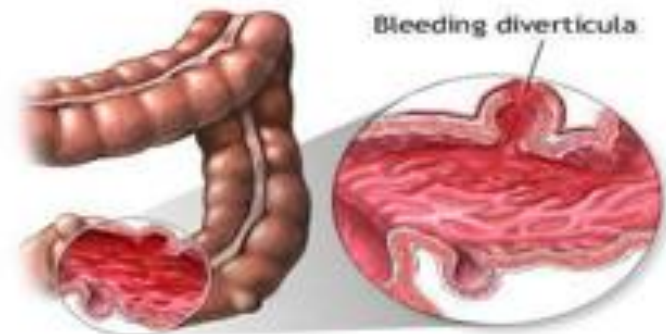
What exactly is a diverticulum?

- True diverticulum contains all layers of the GI wall (mucosa to serosa)

- Colonic pseudo-diverticulum more like a local hernia
 - Mucosa-submucosa herniates through the muscle layer (muscularis propria) and then is only covered by serosa

Introduction

- Most common cause of massive hematochezia (30-50% of cases)
- 15% of patients with diverticulosis will bleed
- 75% of diverticular bleeding stops without need for intervention



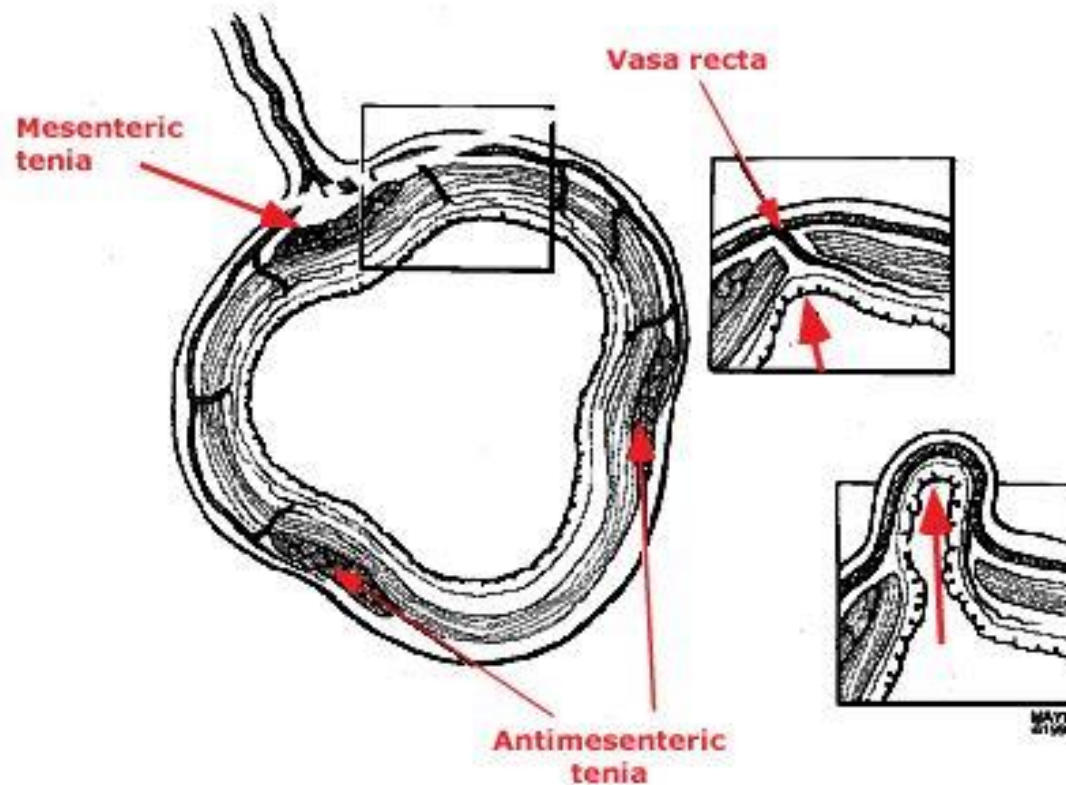
Introduction

- Patients requiring less than 4 units of PRBC/day
→ 99% will stop bleeding
- Risk of rebleeding → 14-38%
- After second episode of bleeding, risk of rebleeding → 21-50%

Pathophysiology

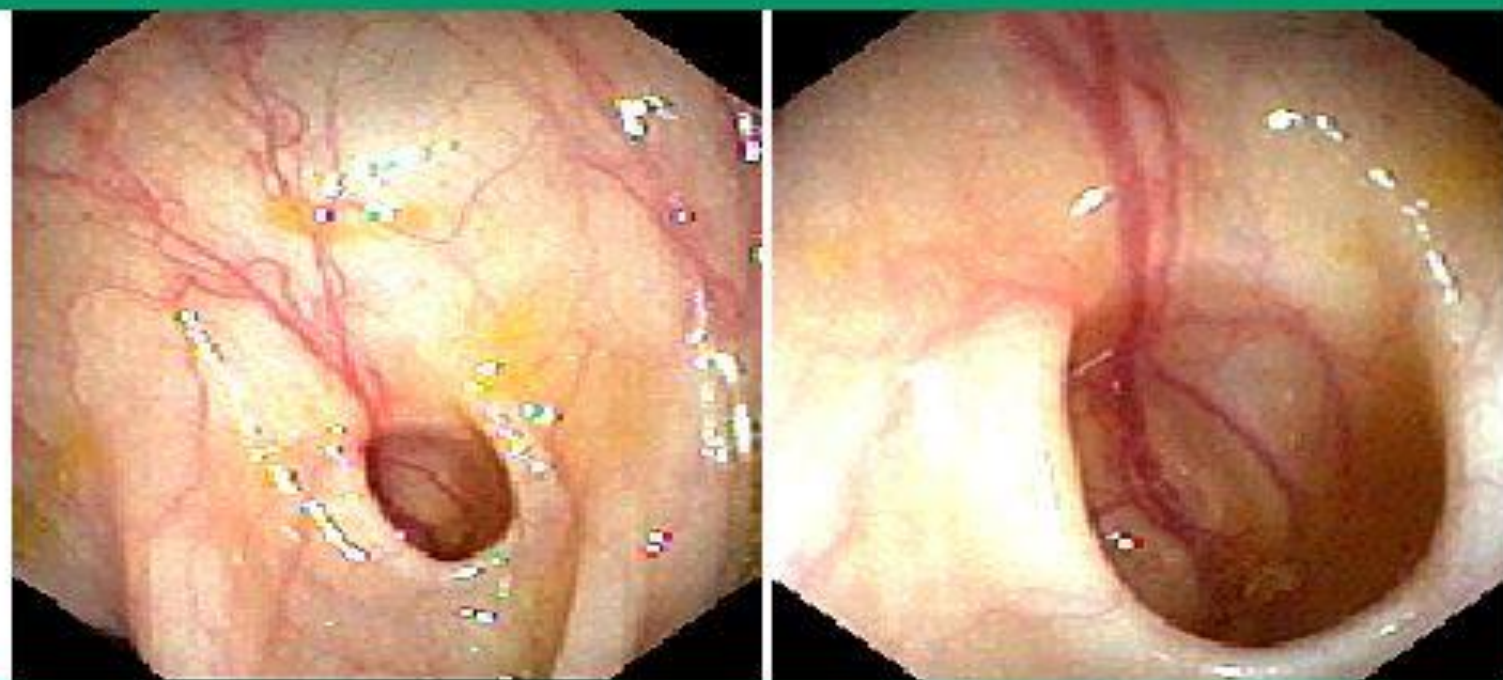- Diverticulum herniates at site of vasa recta
- Overtime, the vessel becomes draped over the dome of the diverticulum separated only by mucosa
- Overtime, there is segmental weakening of the artery
→ ruptures and bleeds

Location of colonic diverticula within the bowel wall



Diverticula develop at four well-defined points around the circumference of the colon, the sites at which the vasa recta penetrate the circular muscle layer. These vessels enter the wall on each side of the mesenteric taenia and on the mesenteric border of the two antimesenteric taeniae. The insets represent the development of a diverticulum at one such point of weakness.

Blood vessel within a colonic diverticulum



Endoscopy showing a blood vessel within a diverticulum. The blood vessel is separated from the bowel lumen only by mucosa. Over time, the vessel wall is exposed to injury along its luminal aspect, possibly leading to segmental weakness which predisposes to rupture into the lumen.

Pathophysiology

- Right colon is the source of diverticular bleeding in 50-90% of patients
- Possible reasons
 - **Right colon diverticuli have wider neck and domes exposing vasa recta over a great length of injury**
 - Thinner wall of the right colon

Symptoms

- Most only have symptoms of bloating and diarrhea but no significant abdominal pain
 - Painless hematochezia
 - Start-stop pattern: “water faucet”
- Diverticulitis rarely causes bleeding



DIAGNOSIS

Technique	Advantages	Disadvantages
Radionuclide imaging	Noninvasive Sensitive to low rates of bleeding Can be repeated for intermittent bleeding	Has to be performed during active bleeding Poor localization of bleeding site Not therapeutic Not widely available
CT angiography	Noninvasive Accurately localizes bleeding source Provides anatomic detail Widely available	Has to be performed during active bleeding Not therapeutic Radiation and IV contrast exposure
Angiography	Accurately localizes bleeding source Therapy possible with super-selective embolization Does not require bowel preparation	Has to be performed during active bleeding Potential for serious complications
Colonoscopy	Precise diagnosis and localization regardless of active bleeding or type of lesion Endoscopic therapy is possible	Need colon preparation for optimal visualization Risk of sedation in acutely bleeding patient Definite bleeding source (stigmata) infrequently identified

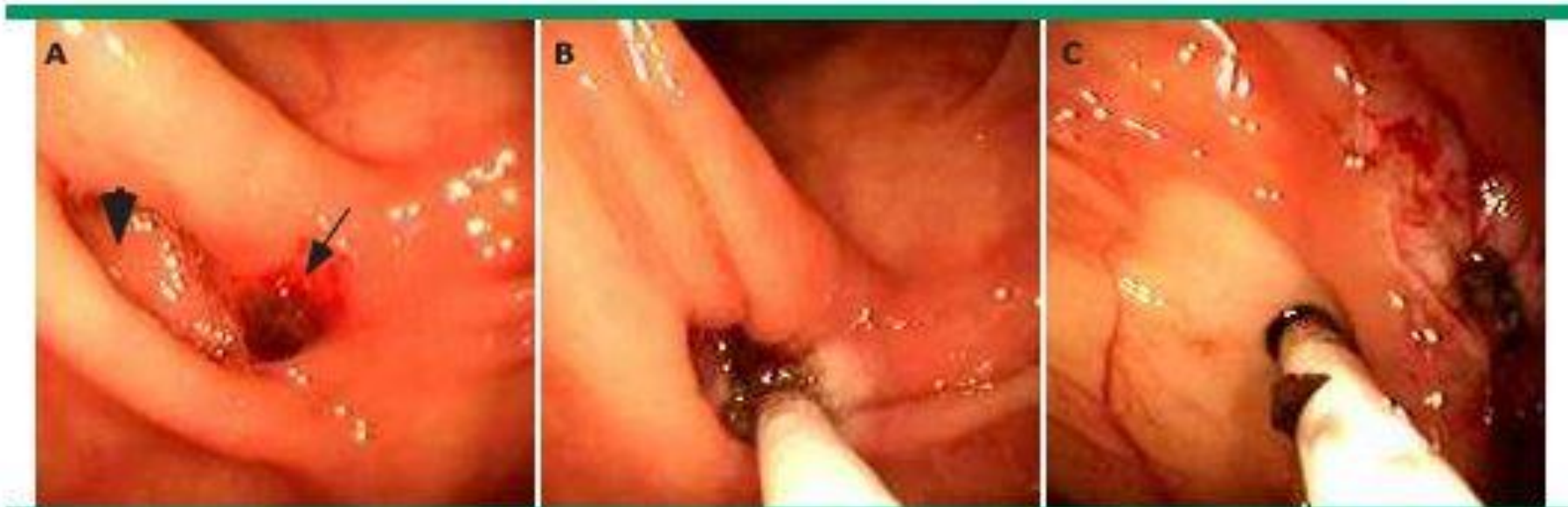MANAGEMENT

- Resuscitation
- Localization and Treatment
 - Endoscopic therapy
 - Angiography
 - Surgical intervention

Endoscopy

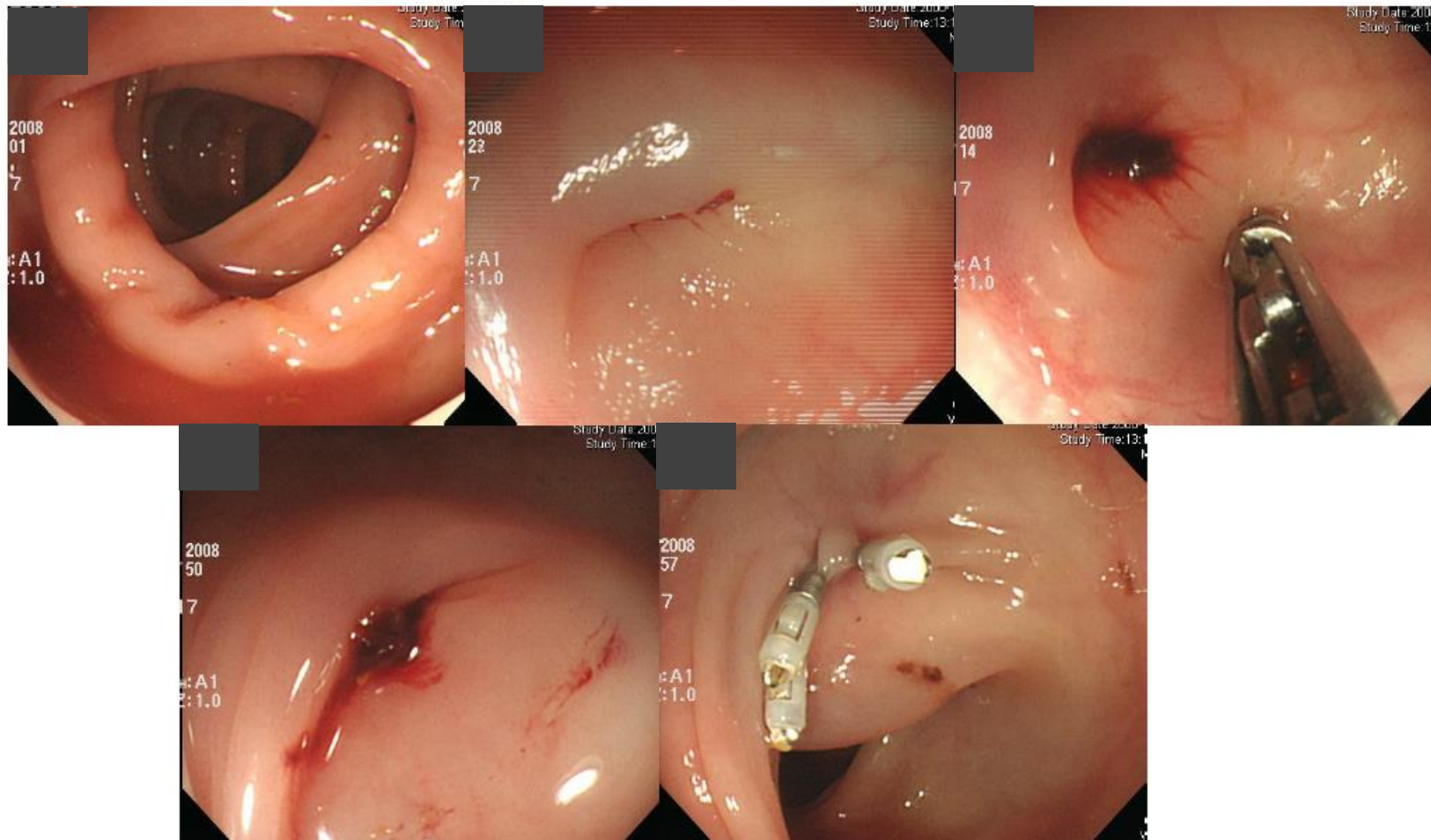
- Colonoscopy after rapid preparation
 - Can localize site of bleeding
 - Offers possible therapeutic intervention (cautery, clip, etc.)
 - Often limited by either brisk bleeding obscuring lumen OR no active bleeding with clots in every diverticuli

Endoscopic therapy



An oozing visible vessel (arrow) can be seen at the mouth of a sigmoid diverticulum (arrowhead, Panel A). The vessel was treated with combination endoscopic therapy using epinephrine injection (1:10,000 dilution) followed by Gold probe electrocautery (Panel B). The area was then tattooed with India ink for easy identification in the event of rebleeding or the need for surgery.

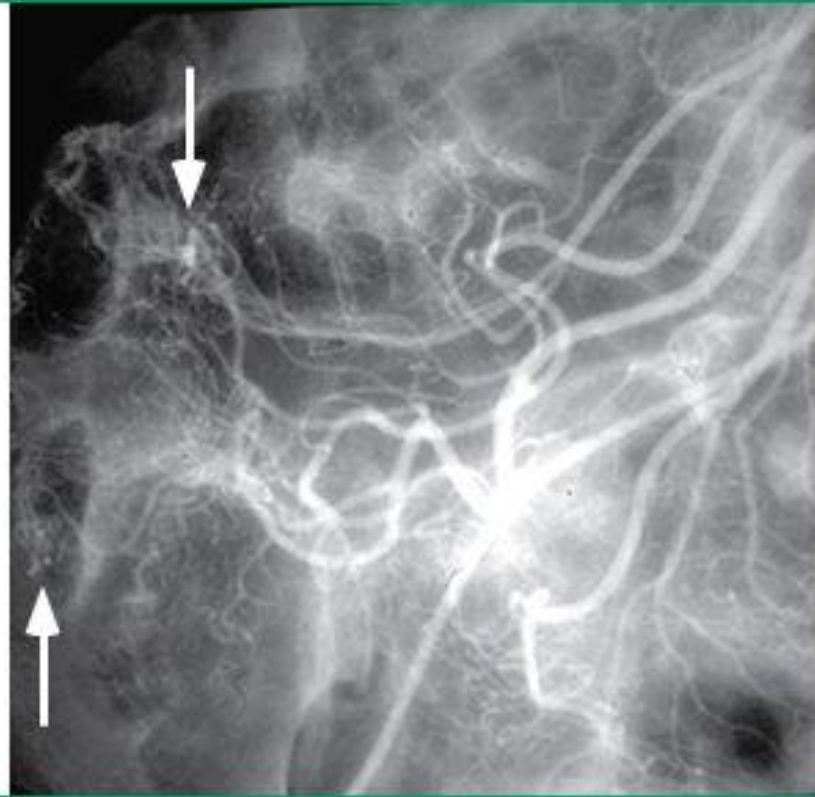
Endoscopic therapy - clipping



Angiography

- Angiography
 - Accurate localization
 - 30-47% sensitive
 - 100% specific
 - Need brisk active bleeding : 0.5-1ml/min
 - Offers therapy: embolization, vasopressin
 - 20% risk of intestinal infarction

Angiography



A superior mesenteric arteriogram demonstrates puddling of contrast material in tortuous distended vessels in the cecal wall (arrows).

Surgery

- Surgery
 - Segmental resection
 - If site can be localized
 - Rebleeding rate of 0-14%
 - Subtotal colectomy
 - Rebleeding rate is 0%
 - High morbidity and mortality

